

Chapter 2

Osteotome Sinus Floor Elevation in Severely-Resorbed Residual Bone and Immediate Implant Placement without Bone Grafting

Saad Al-Almaie

Oral Implantology Unit, King Fahd Military Medical Complex, KSA

***Corresponding Author:** Saad Al-Almaie, Oral Implantology Unit, King Fahd Military Medical Complex, P.O. Box 946, Dhahran 31932, KSA, Tel: +966504805413; Fax: +966-3-8440000; Email: stsralmaie@yahoo.com

First Published **June 30, 2016**

Copyright: © 2016 Saad Al-Almaie.

This article is distributed under the terms of the Creative Commons Attribution 4.0 International License (<http://creativecommons.org/licenses/by/4.0/>), which permits unrestricted use, distribution, and reproduction in any medium, provided you give appropriate credit to the original author(s) and the source.

Abstract

Continuous advancements in the field of implant dentistry have provided clinicians with various treatment options to facilitate the placement of dental implants in patients with vertical bone deficits in the posterior maxilla. Today, one of the most common ways to compensate for inadequate vertical bone height is to elevate the sinus floor by tenting of the schneiderian membrane by the implant which is guided by itself eliminating the need for bone graft. This chapter shows the osteotome sinus-floor elevation and immediate implant placement are also possible in severely resorbed alveolar bone without bone grafting in single or multiple implant placements procedures. Extensive and traumatic conventional lateral approach for sinus lifting and grafting procedures can be avoided even in highly resorbed alveolar bone using this technique. The author hopes that this chapter will prove a valuable resources and references for clinicians placing implants in patients requiring sinus floor elevation in severely resorbed residual bone with simultaneous implant placement without bone grafting to minimize the risk complications and to ensure predictable and stable long term results.

Introduction

Residual ridge resorption following tooth loss, pneumatization of the maxillary sinus and poor quality of the residual alveolar bone are the possible reasons mandating elevation of the maxillary sinus prior to implant

placement [1-3]. Solutions suggested for managing the problem of a vertically-compromised bone volume in the maxillary posterior region include the use of short wide implants, vertical ridge augmentation and lifting the sinus membrane to increase the available length for implant placement [4]. Sinus lifting is intended to increase bone height in the posterior maxilla through formation of new bone in the caudal section of the maxillary sinus [5]. There were two major approaches for the sinus floor augmentation: (the lateral and crestal approaches) [6]. The crestal approach (osteotome technique) is one of the widely practiced techniques for improving the bone density and the quality of the implant site in the posterior maxilla is [7-11]. The osteotome had many disadvantages including limitation of the amount of augmentation of the sinus floor, it is difficult to control the osteotome tapping force while using these techniques in order to produce effective membrane lifting without membrane perforation [12], and all the variations of the osteotome-guided sinus-lifting carry considerable risk of penetrating the sinus membrane while condensing, removing, dissipating, and/or imploding the alveolar bone. Nevertheless, compared to other sinus lifting procedures, the osteotome technique is less invasive and reduces the need for more traumatic and expensive procedures with less risk of damaging the Schneiderian membrane. The implant is inserted simultaneously with a sinus lift procedure only when sufficient primary stabilisation can be expected [13,14].

Jensen and colleagues reported the material and techniques suggested for the various sites and Jensen classes: Classes A and B: Osteotome technique; simultaneous approach; exposed cover screws, Class C: Lateral approach with a barrier membrane; simultaneous (submerged) or delayed (submerged) approach; autogenous graft, alloplasticraft, allo-graft, or xenograft, and Class D: Lateral approach (possibly Le Fort I approach); autogenous grafting (tibial, calvarium, ilium, maxillofacial); delayed approach; submerged cover screws. From different studies, it was reported that “It is useless to use osteotome technique for simultaneous implant placement in a site if few millimeters of bone is available [15-17].” A lateral approach is better in that instance, and a graft should be used. When the simultaneous approach is used, care should be given to maintain the cortical bone during drilling, because it may be the only bone available in the residual basal bone to fixate an implant.

Countersinking of this bone could lead to poor fixation of the implant. The osteotome approach has an advantage of preserving the cortex and compacting the bone [17,18]. It has been recommended that the procedure should be performed with simultaneous implant placement when at least 5 mm of residual subsinus alveolar bone height (RSBH) is present [18]. When less than 5 mm RSBH exists, primary implant stability may be compromised, and implants are placed in a staged fashion at least three to four months later, depending upon the type of

graft materials and volume of bone augmentation. In recent years, the sinus floor elevation (SFE) technique has also been performed using a modified approach, differing from other procedures, in which no graft material is placed in the newly created space underneath the Schneiderian membrane [19-25]. There is a lack of studies evaluating the efficacy of the osteotome technique and the related risk factors that might affect the success of the implant. Therefore this chapter is designed to evaluate the efficacy of the sinus floor elevation with non-invasive sinus crestal approach techniques, nevertheless extensive and traumatic conventional lateral approach for sinus lifting and grafting procedures can be avoided even in highly resorbed alveolar bone using these techniques, and also to show that the osteotome sinus-floor elevation (OSFE) and immediate implant placement are also possible in severely resorbed residual bone (SRRB) without bone grafting.

Classification of the Pre-existing Available Bone Height and Clinical Assessment for Maxillary Sinus

The pre-existing available bone height was classified by different methods to establish an adequate osseous morphologic condition for the placement of endosteal implants in the resorbed maxillary posterior region. Various techniques have been developed to increase bone vol-

ume. In 1987, Misch classified the *subantral* (SA) region of the posterior maxilla in four categories for the treatment of the posterior maxilla (termed subantral [SA]): as SA-1 through SA-4 (Figure 1) [26]. SA-1 has adequate vertical bone for endosteal implants (>12 mm), however the SA-1 posterior maxilla allows implant placement inferior to the sinus cavity without sinus manipulation, thus not altering the sinus floor or membrane. SA-2 has 0 to 2 mm less than ideal height of bone (10 to 12 mm), SA-3 has 5 to 10 mm of bone below the antrum, and SA-4 has less than 5 mm of vertical bone below the maxillary sinus [27].

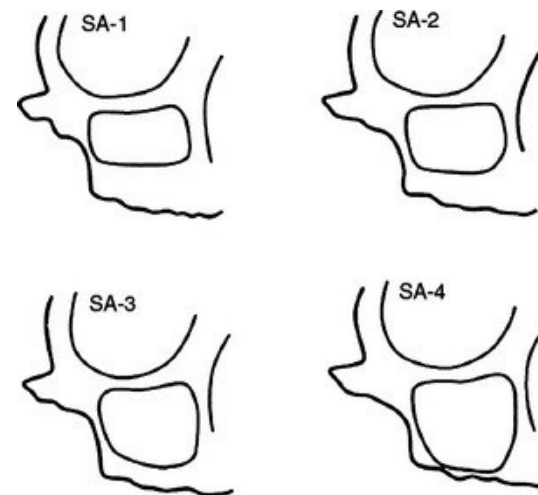
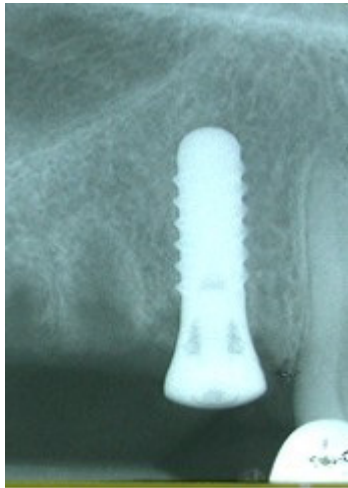
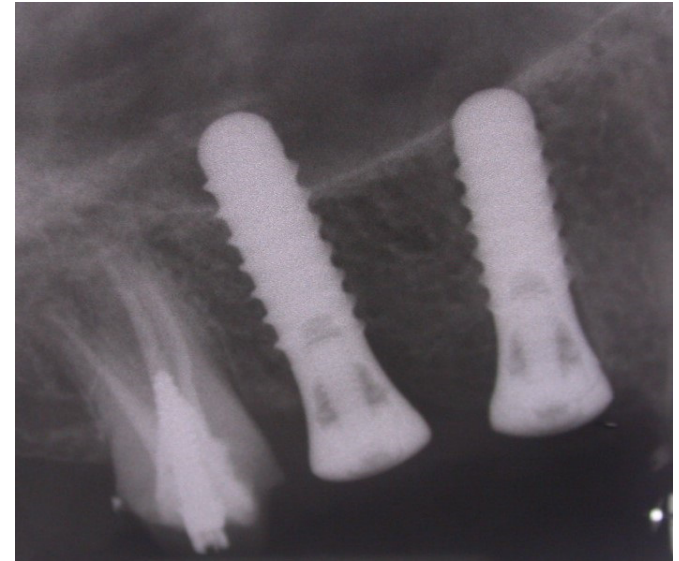
Figure 1: Misch classification for the subantral (SA) region of the posterior maxilla in four categories.

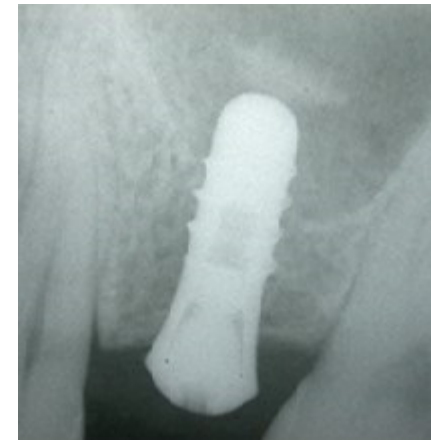Jensen has proposed a classification of sinus morphology (A through E) to help suggest the appropriate grafting material or grafting technique to use, based on a specific site, Class A: 10 mm or more of residual bone present (100% of a 10-mm implant in native bone); Class B: 7 to 9 mm of residual bone present (70% to 90% of a 10-mm implant in native bone); Class C: 4 to 6 mm of residual bone present (40% to 60% of a 10-mm implant in native bone); Class D: 1 to 3 mm of residual bone present (10% to 30% of a 10-mm implant in native bone); Class E: Absent or ablated sinus [15,16] (Figure 2).



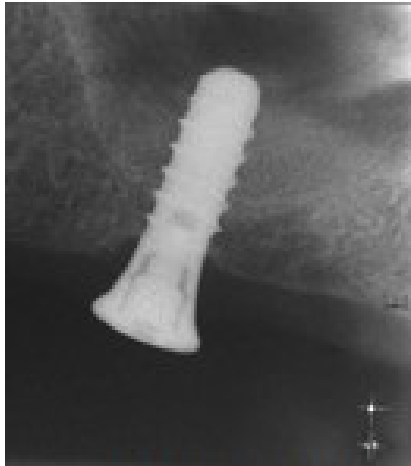
2 (A)



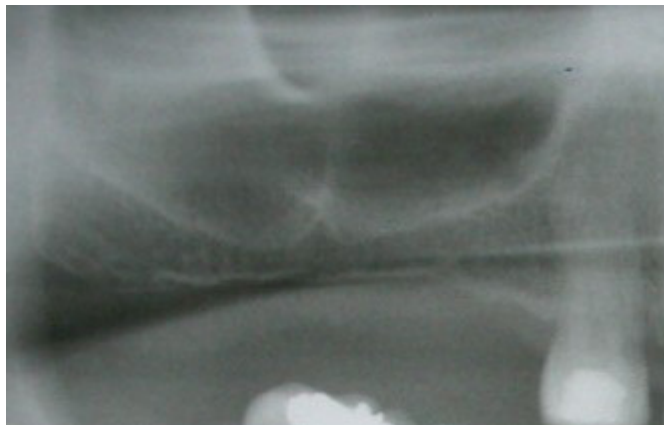
2 (B)



2 (C)



2 (D)



2 (E)

Figure 2: Jensen classification of sinus morphology (A through E) to help suggest the appropriate grafting material or grafting technique to use, based on a specific site.

In 2013 European Association of dental implantologists introduced guideline for the Cologne Classification of Alveolar Ridge Defects (CCARD) which classifies volume deficiencies of the alveolar process regardless of their aetiology as vertical, horizontal and combined defects (H, V, C), possibly in conjunction with a sinus area defect (+S). It takes into account the extent of the augmentation needed (1: < 4 mm, 2: 4-8 mm, 3: > 8 mm) and the relation of graft to surrounding morphology (i: intern, inside the ridge contour vs. e: extern, outside the ridge contour) and makes recommendations on possible treatment approaches based on the current literature [28].

Advantages of Osteotome Technique with Simultaneous Implant Placement in Severely Resorbed Residual Bone

- When little or no grafting material is used, or when only blood clot is present in the sinus floor where the sinus the sinus membrane has been tented up by implants, bone still forms as long as space is maintained beneath an intact sinus lining to form a closed wound environment [7-10,16,29].
- The osteotome technique is, by nature, a less-invasive surgery with smaller flap design and a less extensive osteotomy. Therefore, there is less chance of postoperative complications and morbidity, and patient acceptance for surgery is greatly increased.
- The osteotome technique reduces the need for

more traumatic and expensive procedures with less risk of damaging the Schneiderian membrane.

- In 1996, the report of the Sinus Consensus showed that 48% of failed sinus grafts could be attributed to preoperative complications, and 38% of these were related to sinus-membrane perforation. Ferrigno and Toffler recorded that the rate of osteotome sinus-membrane perforation using the osteotome technique was 2.2% to 4.7% [30,31]. Therefore, the chance of postsurgical complications and infection associated with membrane perforation was greatly reduced.
- The osteotome technique will reduce the chance of osteomeatal complex obstruction because there is a more discrete use of bone in the osteotome technique and less chance of elevating the masses to obstruct the osteomeatal complex.
- More cost-effective and more time-efficient when comparing with an achievement the success rate of 94% to 98% with the lateral-window approach, a resorbable or non-resorbable membrane was needed to cover the osseous lateral window [32]. This increased the cost when compared with internal sinus-lift procedures, which did not require the use of any membrane. Even though the osteotome sinus-lift procedure is an easier, less-invasive and less-costly procedure, there is still concern among clinicians about the amount of the

bone height that can be elevated without membrane perforation for implant placement. There is lower rate of membrane perforation and a less complicated surgery, because osteotome surgery involves a crestal approach, which is common to standard implant surgery.

- The implant is inserted simultaneously with a sinus lift procedure with required initial implant stability.
- To maintain the cortical bone during drilling because it may be the only bone available in the residual basal bone to fixate an im-plant.
- Countersinking of the severely-resorbed residual bone could lead to poor fixation of the implant. The osteotome approach has an advantage of preserving the cortex and compacting the bone.
- Improve the primary stability in cancellous bone by bone condensation through radial reinforcement by a series of bone condensation devices with a tapered tip and an appropriate diameter to widen the implant bed [33]. which the initial stability of implant was attained by lateral condensation however, the quality of bone with a dense cortical plate increases the initial stability.
- Using an expansion osteotome instead of drills to avoid ovalization of the osteotomy site and to condense the surrounding bone [25].

Clinical Performance of Implant Surface and Design

Various techniques of surface treatments have been studied and applied to improved biological surface properties, which favors the mechanism of osseointegration [34,35]. This strategy aims at promoting the mechanism of osseointegration with faster and stronger bone formation, to confer better stability during the healing process, thus allowing more rapid loading of the implant [36,37]. Some of the objectives for the development of implant surface modifications are to improve the clinical performance in areas with poor quantity or quality of bone, to accelerate the bone healing and thereby allowing immediate or early loading protocols and also stimulating bone growth in order to permit implant placement in sites that lack sufficient residual alveolar ridge, thus providing them a jumping gap ability, for example. Implant morphology influences bone metabolism: rougher surfaces stimulates differentiation, growth and attachment of bone cells, and increases mineralization; furthermore, the degree of roughness is important. Implants may have “smooth” (machined) or rough surfaces. The main methods that are reported in the literature to create implant roughness are acid etching, sandblasting surface such as (SLA) dental implant.

- The type of implant surface and design appears to be an important variable in the osteotome technique with simultaneous implant placement in

severely-resorbed residual bone. In the atrophic maxilla, primary stability can readily be achieved with tapered implants, even when the mean residual bone height (RBH) is severely resorbed such as 3.8 mm. The use of the osteotome sinus floor elevation technique without grafting material, combined with the placement of tapered implants, can reduce the need for direct sinus lift procedures. Implants were often placed deeper with the flared neck resting against the crestal bone, which also increased the stability with high percentage of survival and success rates reached in some studies to 100% and 94.4%, respectively [25].

- Buser et al. showed that the SLActive surface promotes earlier bone apposition and provides greater implant stability during the first critical weeks of osseointegration [38], which is more appropriate for osteotome technique with simultaneous implant placement in severely-resorbed residual bone. Bone formation between SLA and SLActive implants was also compared in a study in foxhounds by Bornstein et al. According to it, SLActive demonstrated statistically significantly higher newly formed bone-to-implant contact length than SLA [39].
- The possibility of early loading of sandblasted/Acid-Etched Active surface implant (SLActive) inserted with simultaneous osteotome sinus floor

elevation without the use of grafting material. There is growing interest in early and immediate loading and a reduction time between surgery and prosthetic rehabilitation, especially in areas with atrophic maxilla. However the use of an early loading protocol in the posterior maxilla is doubtful, as this region has always been considered particularly challenging for long-time successful implant survival because of its deficiency in bone quantity and quality [40-44].

- In addition to thread engagement, the body design and surface roughness of the implants provided a frictional interface with the receptor site to assist in the mechanical retention by facilitating bone ingrowth during osseointegration [45].
- According to Ferrigno et al report in 2006, on the relationship of implant survival rate and the length of implants placed with the one-stage osteotome sinus-lift technique (with a total of 588 implants placed in 323 patients with a mean follow-up time of 59.7 months), implants with a 12-mm length had a greater survival rate (93.4%) than 10-mm (90.5%) or 8-mm (88.9%) implants [46,47]. Therefore, it may be desirable to have implants longer than 12 mm when placing fixtures.
- By using the atraumatic technique in the placement of the implant and round-shaped end of the

implant, which limits the risks of damaging the sinus membrane during the sinus lift osteotome procedure. The convex apex shape of the implant is designed to prevent the tearing of the sinus membrane and carefully can elevate the Schneiderian membrane by inserting and placement the implant into the prepared implant bed [48].

Clinical Recommendations and Assessments

- Care should be given, gentle hammering should be performed, and a careful approach should be taken during the osteotome technique to prevent any complication such as the symptoms of vertigo. The patients who were experiencing vertigo were asked to rest in the dental chair for another 15 to 30 minutes prior to discharge from the clinic. Multiple Valsalva tests were performed in all of the cases to check for the patency of the Schneiderian membrane immediately following the procedure. The symptoms of vertigo can require pharmacological management to reduce the spinning sensations and/or the accompanying nausea. The most commonly used drugs are anxiolytics, sedatives, and/or muscle relaxants, along with antihistamines. Antihistamines appear to have suppressive effects on the central emetic center, relieving the nausea and vomiting associated with motion

sickness [49,50]. Patients should be informed regarding the possibility of post-operative vestibular symptoms, because these symptoms can be very unpleasant and may cause considerable stress if the patient is unaware of this problem. If the symptoms are incapacitating, immediate referral to an otorhinolaryngologist is recommended [51-55].

- Meticulous implant insertion should be performed without tapping and cervical laring [48].
- Buser et al. suggested that the omission of tapping in low-density bone would improve primary implant stability [56]. Other authors have proposed using osteotome bone condensation with a smaller than recommended final drill size or placing a submerged implant with its collar in a supracrestal position [57,58]. Vidyasagar et al. avoided tapping and cervical flaring to improve the primary stability of the implant [59]. Avoiding cervical flaring at the preparation site for a placed dental implant even in low-density bone increases the initial implant stability. Nedir et al. reported that tapered implants with a reduced thread pitch were placed with good primary stability in the atrophic maxilla of 2 patients using an osteotome sinus floor elevation procedure without grafting material [60].
- Prior of implant insertion and placement into the appropriate position, a cortical wall was present at

the apical end of the implant, which suggests the formation of a new sinus floor [61]. The regenerative properties of the bone beneath the sinus floor resulted in high endo-sinus bone gain. Some researchers have reported successful sinus elevation without bone grafting, and for all the studied implants, the osteotome procedure without grafting material was effective in forming new bone beyond the original limits of the sinus [24,25,60,62].

Radiological Evaluation and Consideration

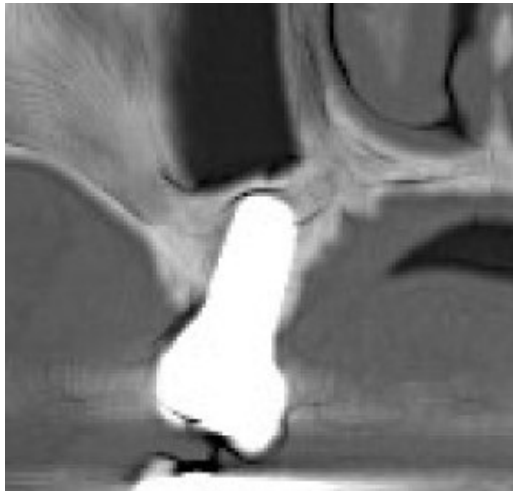The selection of the appropriate radiologic modality must be guided by the anatomic consideration for implant placement in the area under consideration [63,64]. The periapical X-rays revealed adequate bone height and mesio-distal bone width. However, periapical and panoramic radiographs allow visualization of only two dimensions. However computed tomography (CT) scan allows visualization of bucco-lingual (third) dimension, in addition to the other two.

Radiological evaluation revealed sufficient lifting of the sinus floor by osteotome technique and the presence of bone over the implant apex was proved by periapical x-rays (Figure 2-D) and CT scans (Figure 3 Coronal and Sagittal CT scan views).

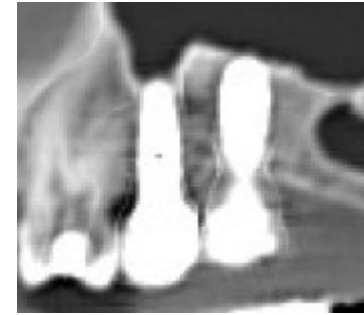Nevertheless, there has been no inconclusive clinical evidence to prove any advantage of bone over the implant

apex directly affecting implant survival in any of the sinus lifting procedures [65,66].

Apical elevation for the sinus floor for osteotome technique was observed radiographically however bone formation at the apex of the implant on periapical radiographs was not always confirmed in the osteotome sinus floor elevation cases and no marked evidence was seen of bone formation between the lifted sinus membrane and the implant apex. Radiological evidence of the presence of bone over the implant apex was proved by CT scans (Figure 3).



CT Scan Coronal view



CT Scan Sagittal View

Figure 3: CT Scan Coronal and Sagittal views.

The CT scan revealed the bucco-lingual width of ridge, with presence of a cancellous bone within initial height of crest. As a comparison between lateral and osteotome approaches, conventional radiography proved bone/graft maturation around the implant apex in cases completed with the lateral approach, while for osteotome sinus floor elevation (OSFE), no marked evidence was seen of bone formation between the lifted sinus membrane and the implant apex. For the lateral approach, the quality and quantity of the bone covering the implant apex might prevent the effects of tangential forces applied on loaded implants, which could eventually initiate crestal bone loss, in which a bone graft is used. In OSFE, because there is no marked bone formation around the implant apex, these tangential forces can apply more rotational force, with a fulcrum situated toward the crestal bone [65,66].

One of the most accurate radiographic assessment for the intact Schneiderian membrane is the reformatted fly-through image of the maxillary sinus floor showed an intact Schneiderian membrane over the projection of the apical border of the implant for all sinus floor elevation techniques which is very appropriate to be used in osteotome technique with simultaneous implant placement in severely-resorbed residual bone and Syngo Siemens Software was used for the thin cut images in the navigation protocol— Fly_through Application for osteotome technique (Figure 4) and for lateral technique (Figure 5) [48,67].

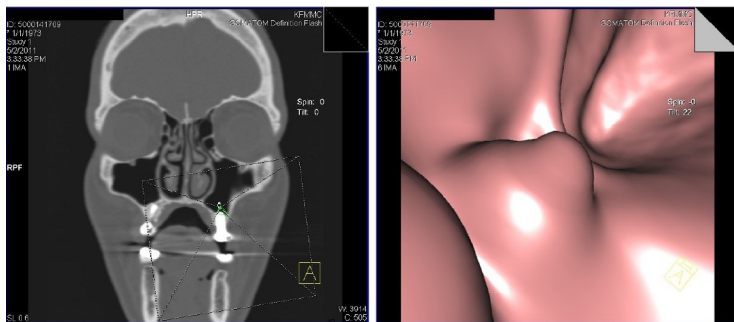


Figure 4: Syngo Siemens Software was used for the thin cut images in the navigation protocol-Fly-through Application–Osteotome technique.

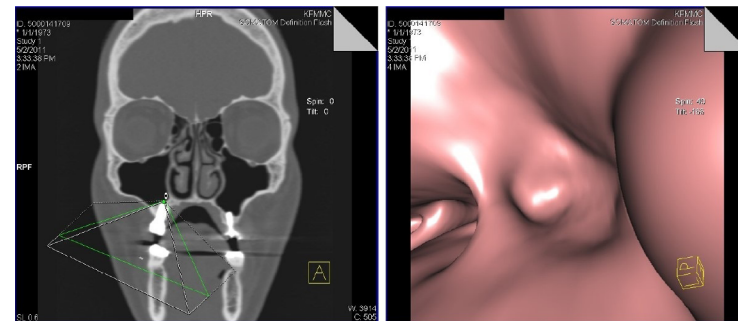


Figure 5: Syngo Siemens Software was used for the thin cut images in the navigation protocol-Fly-through Application–Lateral window technique.

Clinical and radiological data were used to assess implant success on a yearly basis and should successfully fulfilled the Buser et al. criteria [68].

Procedures to Enhance the Osteotome Technique with Simultaneous Implant Placement in Severely-Resorbed Residual Bone

Two procedures can be implemented based on number of dental implants:

Single Implant

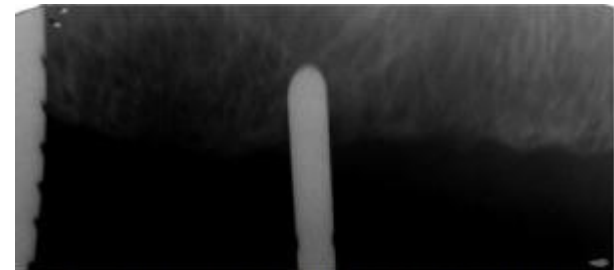
The procedure will be used when one missing tooth should be replaced by one single implant. By doing a small mid-crestal incision at the area of missing tooth and 2 releasing buccal and palatal incisions, the bone can be ac-

cessed and marked with a round bur. A 2.2 mm diameter pilot drill is used to the required depth of 0.5 mm below the roof of the sinus. Radiographs should be taken with a depth gauge and distance indicator to determine the length of the preparation (Figure 6).

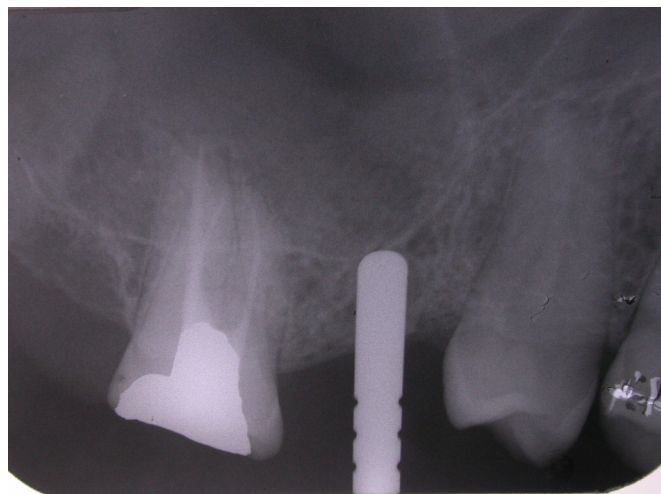
To improve the primary stability in cancellous bone, bone condensation through radial reinforcement could be attained by a series of bone condensation devices with a tapered tip and an appropriate diameter for bone condensation. Malleting could be performed to fracture the bottom of the sinus cavity using an angled osteotome with a concave tip. Change in the resonance during malleting indicated complete osteotomy. The Valsalva test can be used to assess the patency of the Schneiderian membrane and should be negative throughout the procedure. 10 to 12 mm long, wide diameter, wide neck, and nonsubmerged, SLA or SLActive, screw-type implant is more appropriate and provides greater implant stability during the first critical weeks of osseointegration for osteotome technique with simultaneous implant placement in severely-resorbed residual bone. Manual and gentle screwing of the implant can facilitate the lifting of the sinus membrane to the required implant height, and the initial stability can be attained. It is important to assess the implant position, osteotomized portions of the sinus floor, and the amount of sinus floor elevation and should be visible on radiographs (Figure 7).

After implant placement a reformatted flythrough image of the maxillary sinus can be obtained using computed tomography (CT) and DentaScan; reformatted cross-sectional images for the radiographic evaluation of the inferior wall of the maxillary sinus and apical border for the implant area after the osteotome sinus floor elevation to reveal the Schneiderian membrane over the apical border projection of the inserted implant (figure 4).

Different radiographs and CT scans should be taken at 12 and 24 months of prosthetic loading to assess the clinical situation in the area around the apex of the implants. A dome-shaped structure could be observed at the sites of the implant area (Figure 8).



Distal Extension Area



Single Tooth Area

Figure 6: Radiographs were taken with a depth gauge and distance indicator to determine the length of the preparation for surgical implant placement in single tooth and distal extension areas.

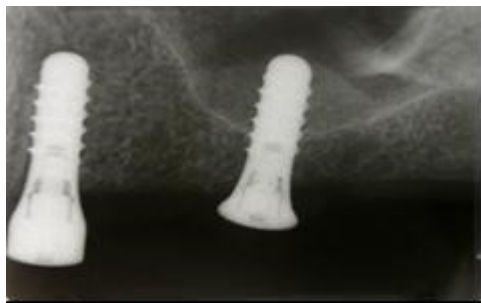

Figure 7: Radiograph shows the amount of sinus floor elevation.

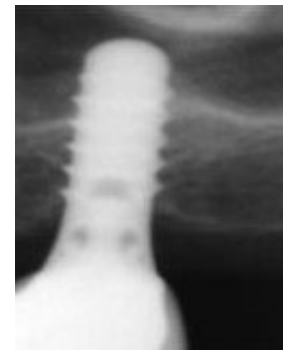

Figure 8: A dome-shaped structure was observed at the site of the implant area.

Multiple Implants

This procedure could be indicated when multiple missing teeth at same quadrant need to be replaced with multiple implant insertion on a severely resorbed alveolar bone height in a staged manner in which the first implant is placed by tenting the sinus membrane using OSFE without a bone graft to prepare the adjacent resorbed sites for further implant placement in the sinus areas, which allows for better initial stability and early functional loading by using staged osteotome technique [48] (Figure 9).

Three to four months after 1st stage of OSFE and simultaneous single implant placement in severely-resorbed residual bone, 2nd stage can be achieved and the procedure was accomplished and resulted in better patient comfort and easier surgical care. Two to three implants could be placed on either side of the first implant.

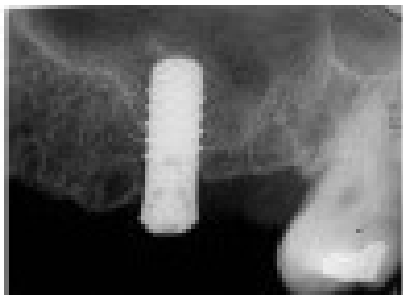


Figure 9: A staged manner in which the first implant is placed by tenting the sinus membrane using OSFE without a bone graft to prepare the adjacent resorbed sites for further implant placement in the sinus areas.

Four months after inserting the implants, radiographs could be taken and showed the implant and surrounding bone under the tented sinus membrane in the first implant region (Figure 10).

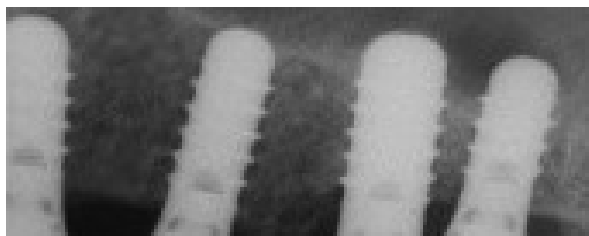


Figure 10: Four months after inserting the implants, radiograph was taken and showed the implant and surrounding bone under the tented sinus membrane in the first implant region.

Periapical radiograph after 12 months of prosthetic loading showing a stable clinical situation in the area around the apex of the implant (Figure 11).

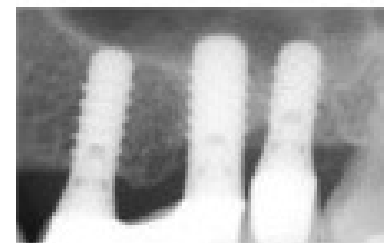


Figure 11: Periapical radiograph after 12 months of prosthetic loading showing a stable clinical situation in the area around the apex of the implant.

The radiographs also can show the transformation of the residual ridge from classes C and D to classes A and B at the medial and distal sides of the implant, respectively.

Elevating the Schneiderian membrane with simultaneous implant placement is sufficient for creating bone beyond the natural limit of the sinus, and that was observed in the 3-month radiological study. This procedure created bone beyond the natural limit of the sinus and facilitated further implant placement by conventional OSFE without risking the loss of initial stability or other complications, such as fractures of the antral floor during malleting.

The least alveolar bone height (less than 3 mm) for the OSFE and immediate placement for just one implant is selected because it is a new procedure and any failure would

not jeopardize or complicate the entire quadrant if more implants were used [48]. This modified method reduced total treatment time, expense of the patients and should be analyzed in further studies.

Prosthodontic Consequences and Osteotome Technique with Simultaneous Implant Placement in Severely-Resorbed Residual Bone

Mechanical guidelines that have been recommended for partial restorations in the posterior segment (to decrease bending moments on implants) may apply to the sinus maxillary situation as well [64]. By optimizing the distribution of forces through implant triangulation, decreased buccal lever arms, and decreased mesial/distal cantilever, the stress on the bone can be reduced. Also, occlusal contacts should be reviewed in relation to the adjacent natural teeth so that the stiffer implant-supported segment does not take a disproportional share of the mastication force [69,70].

These guidelines may be even more important for the sinus area setting than in natural bone because the sinus area with newly bone formation situation inherently incorporates three initial load factors: (1) unfavorable position of the resorbed alveolar bone crest relative to the occlusal contact, (2) initially weak bone supported within the newly bone formation area before this area has de-

veloped its full strength, and (3) the thin-crested cortical bone residual that offers minimal initial fixation for the implant.

In the treatment planning for patients with osteotome technique with simultaneous implant placement in severely-resorbed residual bone, it is therefore essential not include any additional load factors.

Smoking and Maxillary Sinus Floor Elevation

Although smoking habit has been widely discouraged when performing oral surgery specifically in maxillary sinus floor elevation in severely-resorbed residual bone due to its deleterious effects on the wound healing process, regarding implants or tissue integration [71], and the increased risk of suffering postoperative complications such as infection or peri-implantitis [72], it should not be considered an absolute contraindication for implant treatment. This study has found no significant relationship between tobacco and implant failure, including patients whose daily consumption was more than 10 cigarettes per day. Nevertheless, patients should be advised that they are at greater risk of implant failure if they smoke during the initial healing phase following maxillary sinus floor elevation and implant placement and that the interruption of smoking is the best option.

Conclusion

The meticulous management of the available residual bone, the atraumatic sinus lifting procedure, and the proper selection of the implants are the keys to successful dental implantation in severely-resorbed residual bone (SRRB). The author proves that the osteotome sinus-floor elevation in conjunction with implant placement are also possible in (SRRB). Extensive and traumatic conventional lateral approach for the sinus lifting and the grafting procedures can be avoided even in highly resorbed alveolar bone by using these procedures. The attained initial stability favored the early functional loading of the placed implants. This chapter will be of great benefit to clinician in managing patients requiring dental implant in severely-resorbed residual bone (SRRB).

References

1. CE Mich. Dentistry of Bone: Effect on treatment planning, surgical approach and healing. In: Mich CE, editor. Contemporary Implant Dentistry. 1993; 469-485.
2. M Chanavaz. Maxillary Sinus: Anatomy, physiology, surgery and bone grafting related to implantology eleven years of surgical experience (1979-1990). J Oral Implantology. 1990; 16: 199-209.
3. Smiler DG, Johnson PW, Lozada JL, Misch C, Rosenlicht JL, et al. Sinus lift grafts and endosseous implants. Treatment of the atrophic posterior maxilla. Dent Clin North Am. 1992; 36: 151-186.
4. Cavicchia F, Bravi F, Petrelli G. Localized augmentation of the maxillary sinus floor through a coronal approach for the placement of implants. International Journal of Periodontics & Restorative Dentistry. 2001; 21: 475-485.
5. Yadollah Soleymani Shayesteh, Arash Khojasteh, Masoud Soleimani, Marzieh Alikhasi, Ahad Khojshaban, et al. Sinus augmentation using human mesenchymal stem cells loaded into a B-tricalcium phosphate/ hydroxy-apatite scaffold. Oral Surgery, Oral Medicine, Oral Pathology, Oral Radiology. 2008; 106: 203-209.
6. Block MS, Kent JN. Sinus augmentation for dental implants: the use of autogenous bone. J Oral Maxillofac Surg. 1997; 55: 1281-1286.
7. Summers RB. A new concept in maxillary implant surgery: the osteotome technique. Compendium. 1994; 15: 152, 154-156, 158.
8. Summers RB. The osteotome technique: Part 2--The ridge expansion osteotomy (REO) procedure. Compendium. 1994; 15: 422, 424, 426, passim.
9. Summers RB. The osteotome technique: Part 3--Less invasive methods of elevating the sinus floor. Compendium. 1994; 15: 698, 700, 702-704.

10. Summers RB. The osteotome technique: Part 4--Future site development. *Compend Contin Educ Dent*. 1995; 16: 1090, 1092.
11. Summers RB. Sinus floor elevation with osteotomes. *J Esthet Dent*. 1998; 10: 164-171.
12. Yamada JM, Park HJ. Internal sinus manipulation (ISM) procedure: a technical report. *Clin Implant Dent Relat Res*. 2007; 9: 128-135.
13. OH Tatum. Maxillary sinus elevation and subantral augmentation. Lecture Alabama Implant Study Group. Birmingham Ala. 1997.
14. OH Tatum. The Omni Implant System, In: JF (ed), *Clark's Clinical Dentistry*. 1994.
15. Jensen O. Site classification for the osseointegrated implant. *J Prosthet Dent*. 1989; 61: 228-234.
16. Jensen OT. Treatment planning for sinus grafts: In Jensen OT (ed). *The Sinus Bone Graft*. Chicago: Quintessence. 1998; 5.
17. Jensen OT, Sennerby L. Histologic Analysis of Clinically Retrieved Titanium Microimplants Placed in Conjunction with Maxillary Sinus Floor Augmentation. *Int J Oral Maxillofac Implants*. 1998; 13: 513-521.
18. Lekholm U, Zarb CA. Patient Selection and Preparation in Brånemark P-I. In: Zarb GA, Albrek-
tsson T, editors. *Tissue-Integrated Prosthesis: Osseointegration in Clinical Dentistry*. Chicago: Quintessence Publ Co. 1985; 199-209.
19. Bruschi GB, Scipioni A, Calesini G, Bruschi E. Localized management of sinus floor with simultaneous implant placement: a clinical report. *Int J Oral Maxillofac Implants*. 1998; 13: 219-226.
20. S Lundgren, S Anderson, G Gualini, L Sennerby. Bone reformation with sinus membrane elevation: a new surgical technique for maxillary sinus floor augmentation, *Clinical Implant Dentistry and Related Research*. 2004; 6: 165-173.
21. Leblebicioglu B, Ersanli S, Karabuda C, Tosun T, Gokdeniz H. Radiographic evaluation of dental implants placed using an osteotome technique. *J Periodontol*. 2005; 76: 385-390.
22. Li TF. Sinus floor elevation: a revised osteotome technique and its biological concept. *Compend Contin Educ Dent*. 2005; 26: 619-620, 622, 624-626.
23. Ellegaard B, Baelum V, Kølsen-Petersen J. Non-grafted sinus implants in periodontally compromised patients: a time-to-event analysis. *Clin Oral Implants Res*. 2006; 17: 156-164.
24. N Ferrigno, M Laureti, S Fanali, Dental implants placement in conjunction with osteotome sinus

- floor elevation: a 12-year life-table analysis from a prospective study on 588 ITI implants, *Clinical Oral Implants Research*. 2006; 17: 194-205.
25. R Nedir, M Bischof, L Vazquez, S Szmukler-Moncler, JP Bernard. Osteotome sinus floor elevation without grafting material: a 1-year prosthetic pilot study with ITI implant, *Clin Oral Imp Res*. 2006; 17: 679-686.
 26. Misch CE. Maxillary sinus augmentation for endosteal implants: organized alternative treatment plans. *Int J Oral Implantol*. 1987; 4: 49-58.
 27. Misch CE. *Contemporary Implant Dentistry*, 3rd edition. Missouri: Elsevier. 2008.
 28. Peter Ehrl, Ulrich Fürst, Arndt Happe, Fouad Khoury, Pavel Kobler, et al. Cologne Classification of Alveolar Ridge Defects (CCARD). European Association of Dental Implantologists, 8th European Consensus Conference of BDIZ EDI, Cologne. 2013; 2-10.
 29. Lazzara RJ. The sinus elevation procedure in endosseous implant therapy. *Curr Opin Periodontol*. 1996; 3: 178-183.
 30. Ferrigno N, Laureti M, Fanali S. Dental implants placement in conjunction with osteotome sinus floor elevation: a 12-year life-table analysis from a prospective study on 588 ITI implants. *Clin Oral Implants Res*. 2006; 17: 194-205.
 31. Toffler M. Osteotome-mediated sinus floor elevation: a clinical report. *Int J Oral Maxillofac Implants*. 2004; 19: 266-273.
 32. Wallace SS, Froum SJ. Effect of maxillary sinus augmentation on the survival of endosseous dental implants. A systematic review. *Ann Periodontol*. 2003; 8: 328-343.
 33. Rambla-Ferrer J, Peñarrocha-Diago M, Guarinos-Carbó J. Analysis of the use of expansion osteotomes for the creation of implant beds. Technical contributions and review of the literature. *Med Oral Patol Oral Cir Bucal*. 2006; 11: E267-271.
 34. Wong M, Eulenberger J, Schenk R, Hunziker E. Effect of surface topology on the osseointegration of implant materials in trabecular bone. *J Biomed Mater Res*. 1995; 29: 1567-1575.
 35. Wennerberg A, Albrektsson T. On implant surfaces: a review of current knowledge and opinions. *Int J Oral Maxillofac Implants*. 2010; 25: 63-74.
 36. Wennerberg A, Albrektsson T. Effects of titanium surface topography on bone integration: a systematic review. *Clin Oral Implants Res*. 2009; 20 Suppl 4: 172-184.
 37. Beutner R, Michael J, Schwenzer B, Scharnweber D. Biological nano-functionalization of titanium-

- based biomaterial surfaces: a flexible toolbox. *J R Soc Interface*. 2010; 7: S93-S105.
38. Buser D, Broggini N, Wieland M, Schenk RK, Denzer AJ. Enhanced bone apposition to a chemically modified SLA titanium surface. *J Dent Res*. 2004; 83: 529-533.
 39. Bornstein MM, Valderrama P, Jones AA, Wilson TG, Seibl R, et al. Bone apposition around two different sandblasted and acid-etched titanium implant surfaces: a histomorphometric study in canine mandibles. *Clin Oral Implants Res*. 2008; 19: 233-241.
 40. Adell R, Lekholm U, Rockler B, Brånemark PI. A 15-year study of osseointegrated implants in the treatment of the edentulous jaw. *Int J Oral Surg*. 1981; 10: 387-416.
 41. Bahat O. Treatment planning and placement of implants in the posterior maxillae: report of 732 consecutive Nobelpharma implants. *Int J Oral Maxillofac Implants*. 1993; 8: 151-161.
 42. Bahat O. Brånemark system implants in the posterior maxilla: clinical study of 660 implants followed for 5 to 12 years. *Int J Oral Maxillofac Implants*. 2000; 15: 646-653.
 43. Bass SL, Triplett RG. The effects of preoperative resorption and jaw anatomy on implant success. A report of 303 cases. *Clin Oral Implants Res*. 1991; 2: 193-198.
 44. Friberg B, Jemet T, Lekholm U. Early failures in 4,641 consecutively placed Branemark dental implant. A study from stage 1 surgery to the connection of completed prostheses. *Int J Oral Maxillofac Implants*. 1991; 6: 142-146.
 45. Buser D, Nydegger T, Oxland T, Cochran DL, Schenk RK, et al. Interface shear strength of titanium implants with a sandblasted and acid-etched surface: a biomechanical study in the maxilla of miniature pigs. *J Biomed Mater Res*. 1999; 45: 75-83.
 46. Ferrigno N, Laureti M, Fanali S. Dental implants placement in conjunction with osteotome sinus floor elevation: a 12-year life-table analysis from a prospective study on 588 ITI implants. *Clin Oral Implants Res*. 2006; 17: 194-205.
 47. Reiser GM, Rabinovitz Z, Bruno J, Damoulis PD, Griffin TJ. Evaluation of maxillary sinus membrane response following elevation with crestal osteotome technique in human cadavers. *Int J Oral Maxillofac Implants*. 2001; 16: 833-840.
 48. S Al-Almaie S. Staged Osteotome Sinus Floor Elevation for Progressive Site Development and Immediate Implant Placement in Severely Resorbed Alveolar Bone: A Case Report. *Case Rep Dent*. 2013; 2013: 310931.
 49. Bhattacharyya N, Baugh RF, Orvidas L, Barrs D, Bronston LJ. Clinical practice guideline: benign

- paroxysmal positional vertigo. *Otolaryngol Head Neck Surg.* 2008; 139: S47-81.
50. Saker M, Ogle O. Benign paroxysmal positional vertigo subsequent to sinus lift via closed technique. *J Oral Maxillofac Surg.* 2005; 63: 1385-1387.
 51. Kim MS, Lee JK, Chang BS, Um HS. Benign paroxysmal positional vertigo as a complication of sinus floor elevation. *J Periodontal Implant Sci.* 2010; 40: 86-89.
 52. Sammartino G, Mariniello M, Scaravilli MS. Benign paroxysmal positional vertigo following closed sinus floor elevation procedure: mallet osteotomes vs. screwable osteotomes. A triple blind randomized controlled trial. *Clin Oral Implants Res.* 2011; 22: 669-672.
 53. Vernamonte S, Mauro V, Vernamonte S, Messina AM. An unusual complication of osteotome sinus floor elevation: benign paroxysmal positional vertigo. *Int J Oral Maxillofac Surg.* 2011; 40: 216-218.
 54. Ramakrishna J, Goebel JA, Parnes LS. Efficacy and safety of bilateral posterior canal occlusion in patients with refractory benign paroxysmal positional vertigo: case report series. *Otol Neurotol.* 2012; 33: 640-642.
 55. Reddy K S, Shivu ME, Billimaga A. Benign paroxysmal positional vertigo during lateral window sinus lift procedure: a case report and review. *Im-plant Dent.* 2015; 24: 106-109.
 56. Buser D, Schenk RK, Steinemann S, Fiorellini JP, Fox CH, et al. Influence of surface characteristics on bone integration of titanium implants. A histomorphometric study in miniature pigs. *Journal of Biomedical Materials Research.* 1991; 25: 889-902.
 57. Martinez H, Davarpanah M, Missika P, Celletti R, Lazzara R. Optimal implant stabilization in low density bone. *Clin Oral Implants Res.* 2001; 12: 423-432.
 58. O'Sullivan D, Sennerby L, Meredith N. Measurements comparing the initial stability of five designs of dental implants: a human cadaver study. *Clin Implant Dent Relat Res.* 2000; 2: 85-92.
 59. Vidyasagar L, Salms G, Apse P, Teibe U. The influence of site preparation (countersinking) on initial dental implant stability, an in vitro study using resonance frequency analysis. *Stomatologija.* 2004; 6: 14-16.
 60. Nedir R, Nurdin N, Szmukler-Moncler S, Bischof M. Osteotome sinus floor elevation technique without grafting material and immediate implant placement in atrophic posterior maxilla: report of 2 cases. *Journal of Oral and Maxillofacial Surgery.* 2009; 67: 1098-1103.
 61. Biscaro L, Beccatelli A, Landi L. A human histologic report of an implant placed with simultaneous sinus floor elevation without bone graft. In-

- ternational Journal of Periodontics & Restorative Dentistry. 2012; 32: e122-e130.
62. Sohn DS, Moon JW, Moon KN, Cho SC, Kang PS. New bone formation in the maxillary sinus using only absorbable gelatin sponge. *J Oral Maxillofac Surg.* 2010; 68: 1327-1333.
 63. Kraut RA. Interactive radiologic diagnosis and case planning for implants. *Dent Implantol Update.* 1994; 5: 49-55.
 64. Borrow JW, Smith JP. Stent marker material for computer tomograph-assisted implant planning, *Int J Periodontics Restorative Dent.* 1996; 16: 61.
 65. Hatano N, Shimizu Y, Ooya K. A clinical long-term radiographic evaluation of graft height changes after maxillary sinus floor augmentation with a 2:1 autogenous bone/xenograft mixture and simultaneous placement of dental implants. *Clin Oral Implants Res.* 2004; 15: 339-347.
 66. Pjetursson BE, Ignjatovic D, Matulienė G, Brägger U, Schmidlin K. Transalveolar maxillary sinus floor elevation using osteotomes with or without grafting material. Part II: Radiographic tissue remodeling. *Clin Oral Implants Res.* 2009; 20: 677-683.
 67. Al-Almaie S, Kavarodi A, Al Faidhi A. Maxillary sinus functions and complications with lateral window and osteotome sinus floor elevation procedures followed by dental implant placement: A retrospective study in 60 patients. *J of Contemporary Dental Practice.* 2013; 14: 405-413
 68. Buser D, Weber HP, Braegger U. The treatment of partially edentulous patients with ITI hollow-screw implants; presurgical evaluation and surgical procedures. *Int J Oral Maxillofac Implants.* 1990; 5: 165-174.
 69. Rangert B. Load factor analysis for implants in resorbed posterior maxilla. In: Jensen OT (ed). *The sinus Bone Graft.* Chicago: Quintessence. 1998; 14.
 70. Dallenbach KI, Hurley E, Brunski J, Rangert B. Biomechanical of in-line vs offset implants supporting partial prosthesis (abstract). *J Dent Rest.* 1996; 75(special issue) 1327:183.
 71. Lindquist LW, Carlsson GE, Jemt T. Association between marginal bone loss around osseointegrated mandibular implants and smoking habits: a 10-year follow-up study. *J Dent Res.* 1997; 76: 1667-1674.
 72. Lin TH, Chen L, Cha J, Jeffcoat M, Kao DW, et al. The effect of cigarette smoking and native bone height on dental implants placed immediately in sinuses grafted by hydraulic condensation. *Int J Periodontics Restorative Dent.* 2012; 32: 255-261.