

Chapter 1

Pre-Surgical Diagnosis and Planning for Implant Restorations: Preventing Surgical and Prosthetic Complications

Stefanos Kourtis

Department of Prosthodontics, University of Athens, Greece

***Corresponding Author: Stefanos Kourtis**, Dept. of Prosthodontics, University of Athens, Greece, Email: stefkour@dent.uoa.gr

First Published **May 12, 2016**

Copyright: © 2016 Stefanos Kourtis.

This article is distributed under the terms of the Creative Commons Attribution 4.0 International License (<http://creativecommons.org/licenses/by/4.0/>), which permits unrestricted use, distribution, and reproduction in any medium, provided you give appropriate credit to the original author(s) and the source.

Introduction

In the early days of clinical application of osseointegration, implants were placed in areas where bone quantity was adequate and the prosthetic restoration was a screw-retained Fixed Partial Denture (FPD). The evolution of prosthetic components and the technique of Guided Tissue Regeneration have offered increased possibilities in implant restorations. Proper presurgical diagnosis remains however a crucial stage when planning an implant restoration [1-4]. For these reasons a close cooperation between the clinician and the dental technician is needed to plan and predict a functional and esthetic outcome [5-6].

The aim of the treatment planning is to establish the kind and extend of the prosthetic restoration, which will dictate the number, position and inclination of the needed implants. For this reason presurgical planning has to be accomplished in details using all available means that contemporary technology may offer [7]. Numerous techniques have been proposed for the fabrication of radiographic and surgical templates (also referred as guides, splints or stents) using various radiopaque materials as markers [8-13].

- Presurgical diagnosis for implant treatment includes:
- Panoramic x-ray with a determined magnification
- Study casts mounted on a semi-adjustable articulator

- Detailed wax-up/ set-up
- Radiographic template
- CT- Dental Scan
- Periapical x-rays (if a maximum detail is necessary)
- Surgical template

If the presurgical examination is not detailed, the clinician may encounter unexpected difficulties during treatment, either in the surgical or in the prosthetic phase.

Dental scan examination using a Cone Beam Computer Tomography (CBCT) is considered nowadays as a standard procedure for precise and detailed examination of the bone substrate prior to implant placement. It should be combined with the use of a radiopaque template and followed by a correct reconstruction to produce accurate cross-section images of the examined region [14-15].

Aim

The aim of this chapter is to focus on detailed pre-surgical planning taking under consideration all case-specific details. The presented cases were selected because each one had one or more complicated stages that could be recognized during the planning phase avoiding further complications.

The following cases represent some indicative examples to emphasize the need of careful examination and

planning. Beside the zone of implantation, a thorough intraoral examination is necessary to recognize the whole area of the planned restoration. Anatomical structures, interarch relationship, occlusal situation in the whole dental arch should be carefully evaluated before initiation of the treatment. In certain cases an extra oral examination may also reveal some factors that have to be taken under consideration during the treatment planning.

The clinician should always combine the information from all the above mentioned presurgical means of examination in order to establish a solid and predictable treatment plan that should focus on the difficult points of each case and also include alternative treatment options. In the following cases it is shown how each diagnostic tool and the combined information can and should be evaluated before any irreversible treatment step is undertaken.

Case A (Figures 1-8)

The patient presented for restoration of the mandibular left quadrant. The patient wished a fixed restoration instead of the existing removable partial denture. The initial clinical and radiographic examination revealed an alveolar crest with reduced height and severely absorbed in width (Figures 1-4). The occlusal relation was found acceptable without need of excessive occlusal corrections except for the canine areas # 23/33.

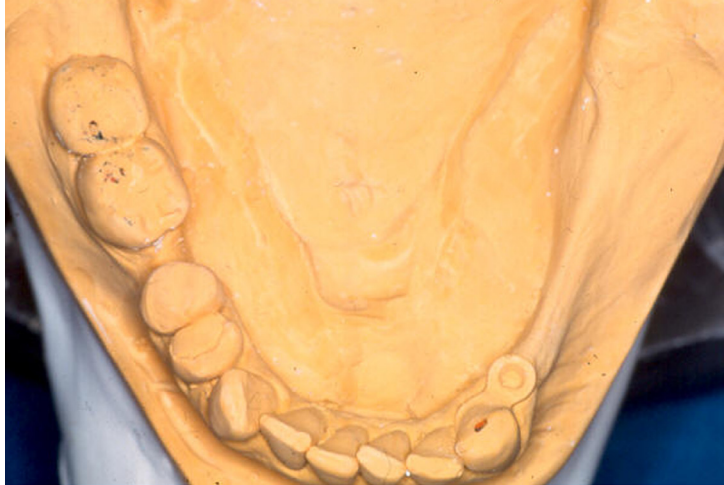

Figure 1

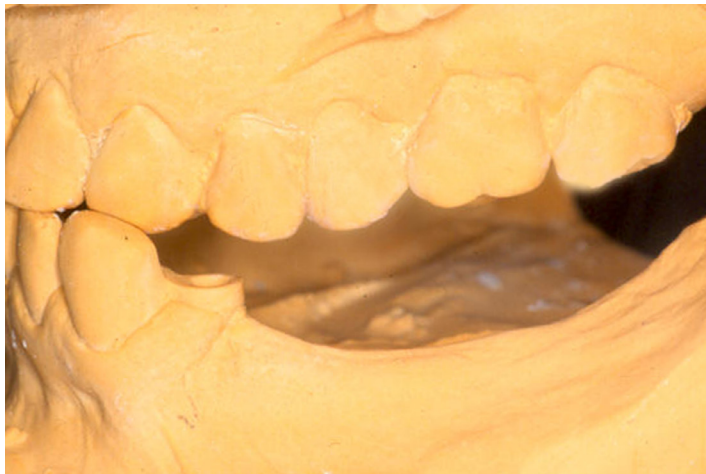

Figure 2

Figure 1 and Figure 2: Case A: Study casts of the patient. Bone resorption is obvious, both in height and width.

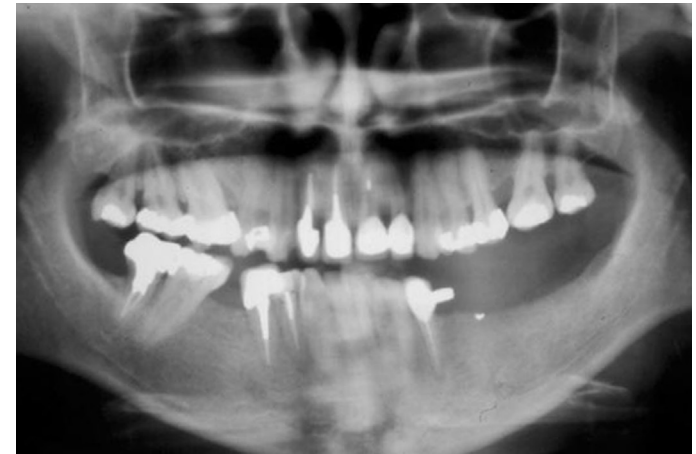

Figure 3

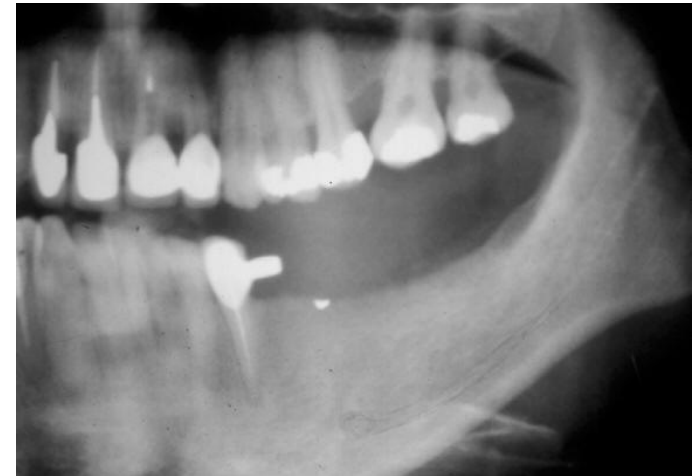


Figure 4

Figure 3 and Figure 4: Panoramic x-ray of the patient. The height of the alveolar ridge allows implants with adequate length.

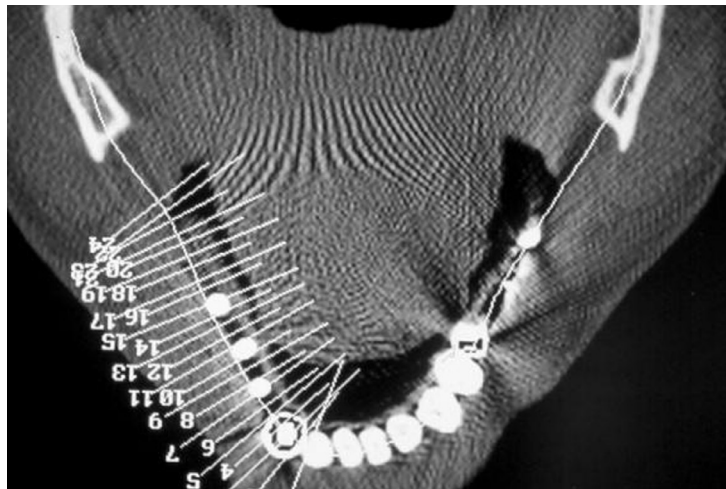


Figure 5

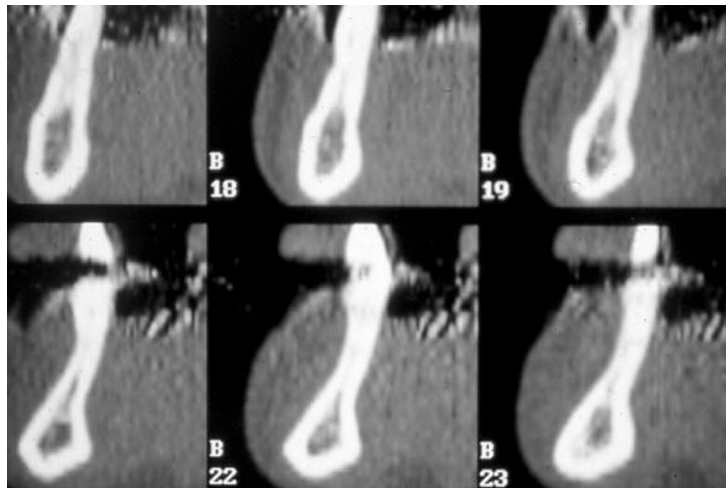


Figure 6

Figure 5 and Figure 6: Ct-Scan of the patient. The alveolar ridge is severely resorbed in width and lateral augmentation is needed.

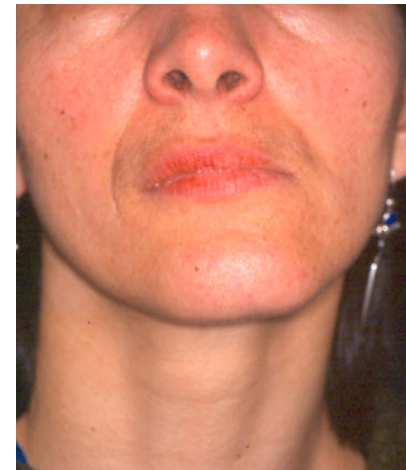

Figure 7

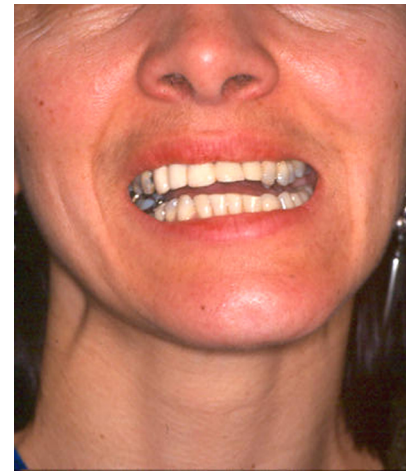


Figure 8

Figure 7 and Figure 8: Extra-oral examination of the patient. Face asymmetry is obvious along the midline of the face and also a lateral shift of the mandible to the left side is intense during mouth opening.

The CT-Dental Scan showed that an augmentation procedure on the labial side was necessary to allow placement of the implants as there was minimal spongy bone between the cortical plates (Figures 5-6). Before any treatment procedure, the patient was carefully examined to verify the extent and expected efficacy of the augmentation procedure on the planned restoration. In the extra oral examination an asymmetry of the face was observed and the patient's mandible showed an inclined path during mouth opening to the left side (Figures 7-8). Any labial augmentation procedure on the left side of the mandible would increase the asymmetry of the face and could possibly compromise the esthetic of the face. All these factors were explained to the patient who denied any further treatment that could affect the facial esthetic.

Case B (Figures 9-14)

The patient presented for treatment of the edentulous posterior areas of the maxilla and the mandible on the left side (Figure 9). The initial clinical examination revealed a normal alveolar crest with minimum absorption both in height and width, as the extractions were performed several months ago, as could also be observed on the study casts (Figure 10). On the initial panoramic x-ray the bone density and quantity seemed adequate for implant placement. However the contrast and the inclination of the x-ray seemed questionable (Figure 11a).

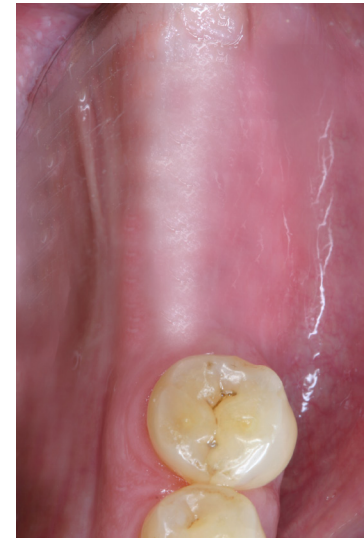

Figure 9: Case B: Initial clinical situation.

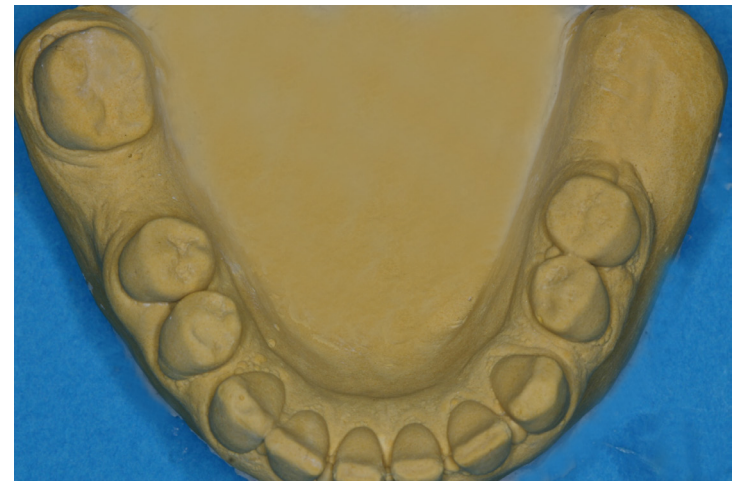
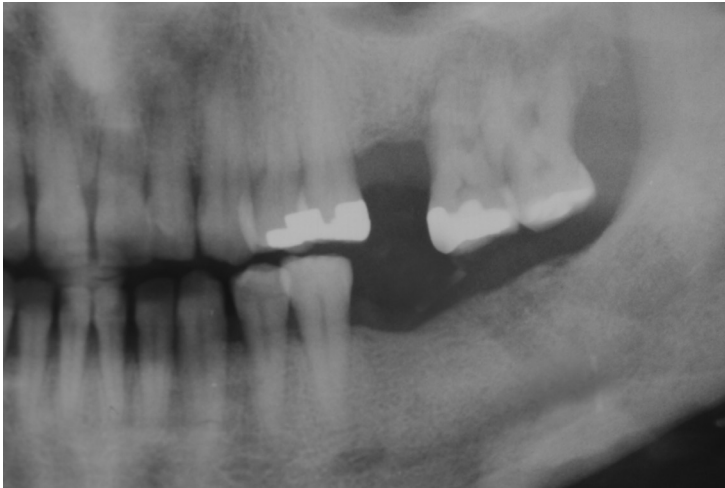
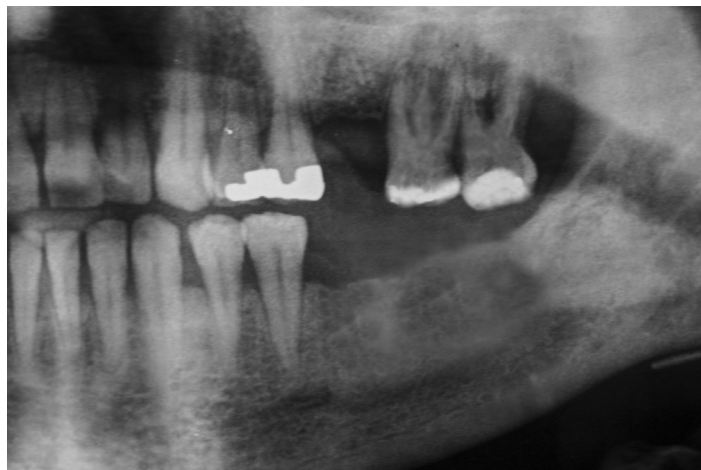
Figure 10: Mandibular study cast.



11 (a)



11 (b)

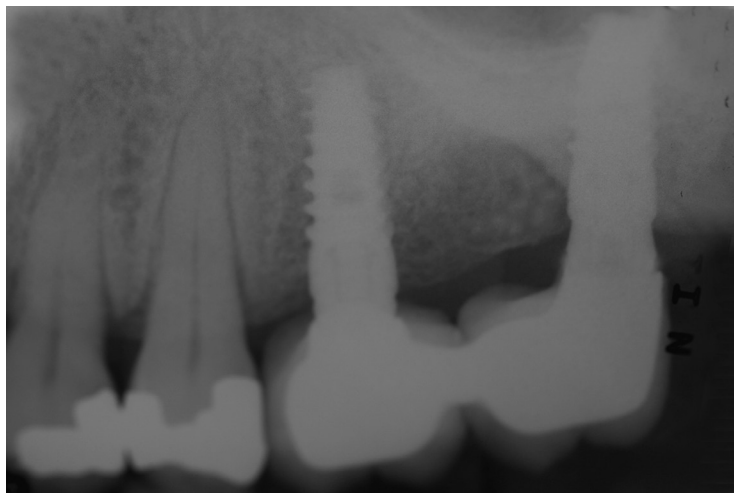
Figure 11: Initial (a) and secondary (b) panoramic x-ray of the patient.

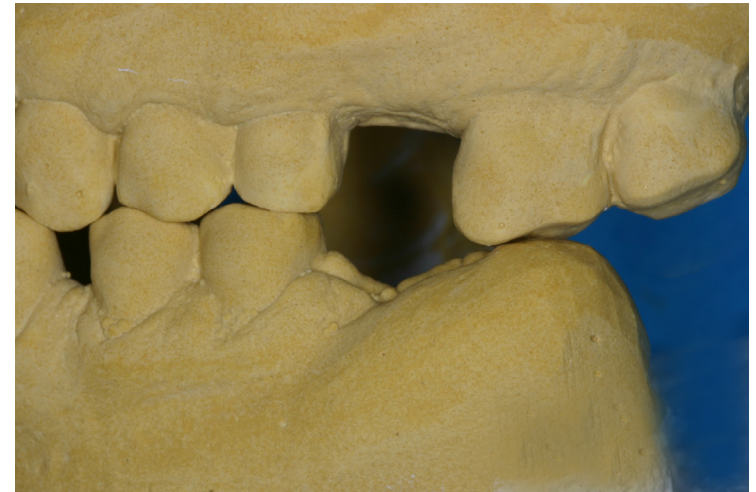

Figure 12: Study casts mounted on the articulator.

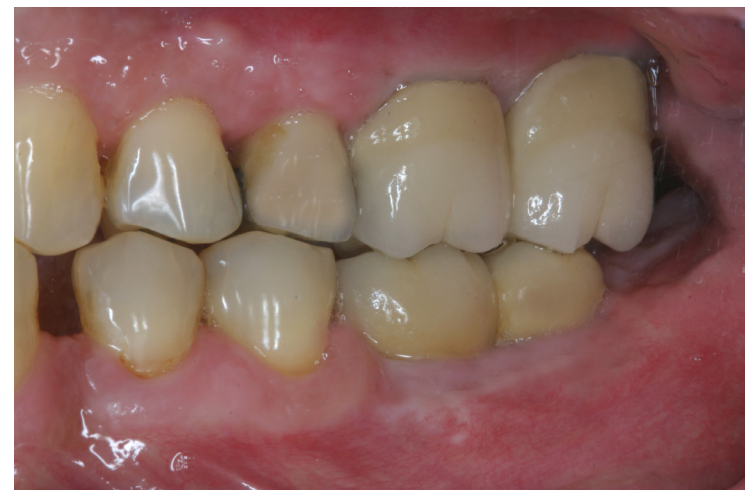

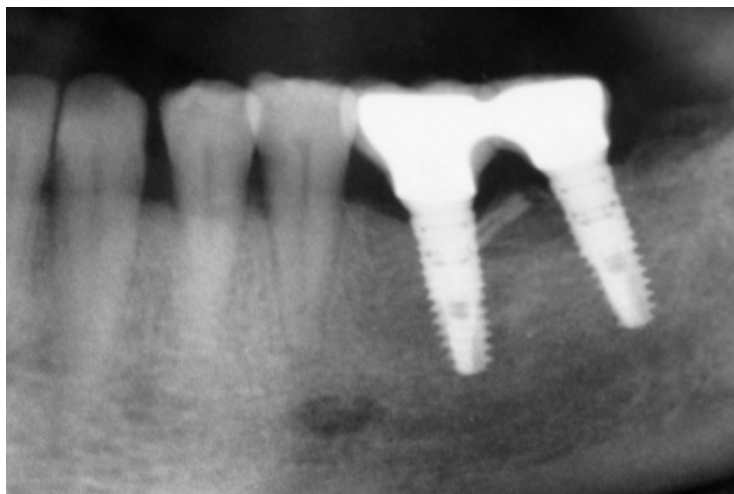Figure 13: The final restoration.



14 (a)



14 (b)

Figure 14a and 14b: Radiographic control at the recall.

The maxillary posterior teeth # 27 and 28 were overerupted, protruding in the occlusal level. The patient insisted for maintaining of the maxillary teeth and implant insertion in area #26. The initial treatment planning for the maxilla included endodontic treatment of teeth # 27 and 28, metal-ceramic crowns to the proper height according to the occlusal level and a single tooth implant in area # 26. In the mandible two single tooth implants were planned in areas # 36 and 37. As the treatment plan included extensive tooth preparation and a fixed restoration with increased cost, a new panoramic x-ray with better quality and sharpness was performed (Figure 11b). The new x-ray revealed several endodontic and periodontic problems of the maxillary left molars.

Study casts were fabricated and mounted on a semi-adjustable articulator (Figure 12). On the study casts the degree of overeruption of the maxillary molars was re-evaluated combined with the new x-ray. The prognosis of the molars was doubtful to poor due to periodontal condition and furcation problems. If the teeth should be maintained—according to the patient's wish—extensive periodontal treatment including bone surgery would be mandatory and the prognosis would remain doubtful. Additionally root canal treatment and crown restoration would be necessary for both teeth 26 and 27, while their prognosis would remain doubtful.

Based on these observations, a new treatment plan was made that included extraction of both maxillary mo-

lars and insertion of two implants in areas # 26 and 27. As these teeth were overerupted, the bone absorption after extraction with minimum osteoplastic surgery would compensate for proper interarch space in the area. On the other side the maxillary implants would have a better prognosis compared to the existing teeth in the present situation. Soft tissue surgery to reduce gingival thickness was also decided for the left distal side of the mandible that could be accomplished simultaneously to implant insertion (Figure 12).

Both treatment plans were presented to the patient with details in all aspects. The patient consented for extraction of the teeth and insertion of two implants in the maxilla and two in the mandible. The case could be accomplished uneventfully (Figure 13 and Figure 14).

Case C (Figures 15-18)

The patient presented for restoration of the edentulous posterior areas in the mandible. Following the initial clinical examination and panoramic x-ray (Figure 15) study casts were fabricated to evaluate the resorption of the alveolar space, the available interarch space and the occlusal relationship (Figure 16 and Figure 17). The available vertical space was extremely reduced due to over-eruption of the antagonist teeth. In order to restore the occlusal level on the maxillary teeth, segmental osteotomy was necessary bilaterally. As it was shown on the CT-Dental Scan, the severe bone resorption of the alveolar ridges imposed vertical and horizontal augmentation procedure (Figure 18).

The treatment plan was explained to the patient; four surgical steps would be necessary for proper implant placement and increased time would be needed to the final restoration. Alternatively, a full-mouth restoration including all maxillary and mandibular teeth should be undertaken in an increased vertical dimension to compensate the limited interarch space. The patient preferred to retain the existing removable partial denture.

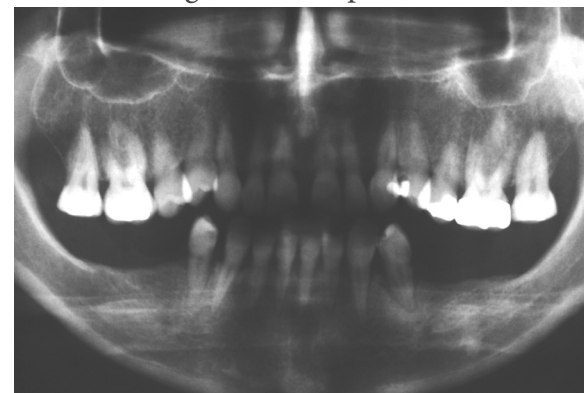


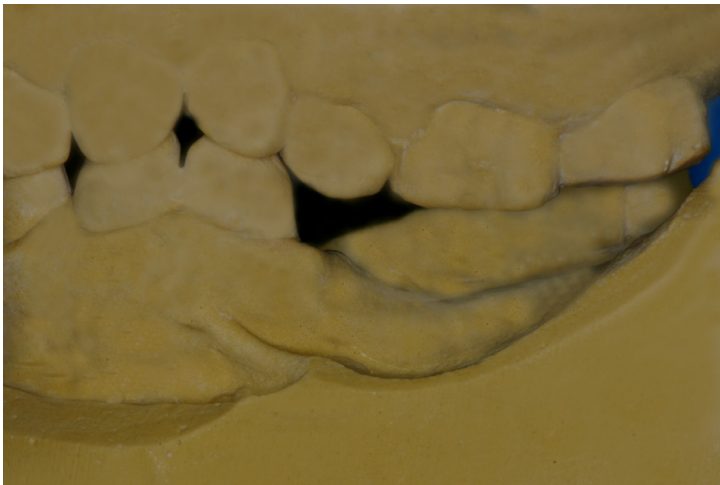
Figure 15: Case C: Initial panoramic x-ray.

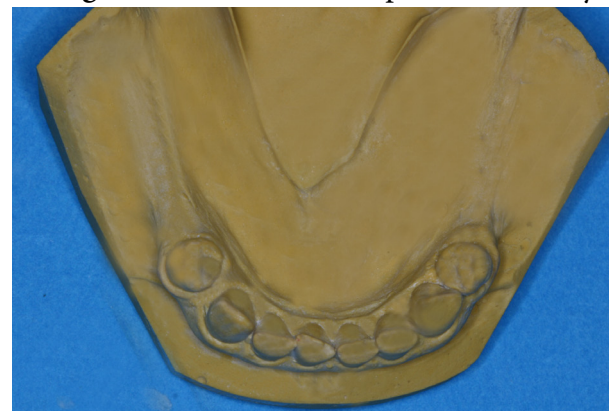
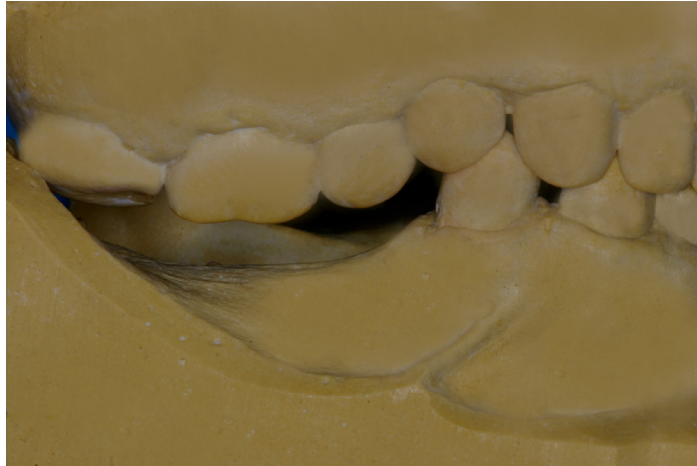
Figure 16: Study cast of the mandible.

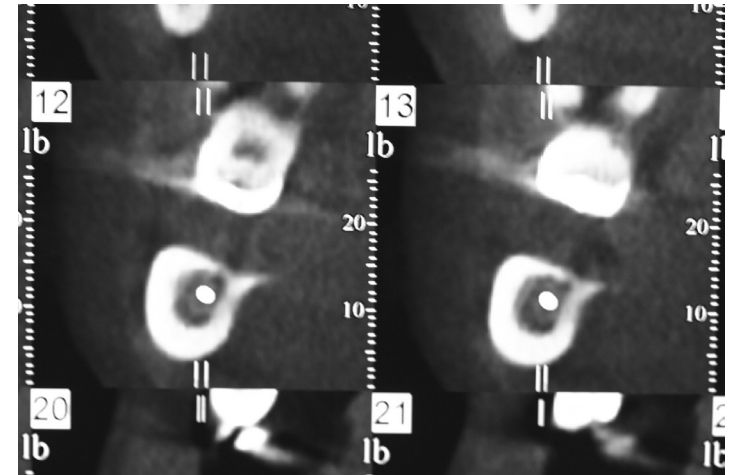


17 (a)

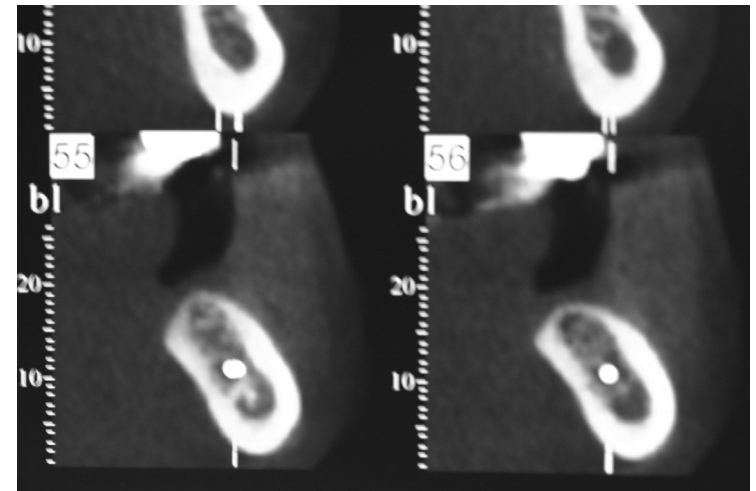


17 (b)

Figure 17a and 17b: The study casts mounted on the articulator in maximum intercuspation.



18 (a)



18 (b)

Figure 18a and 18b: Reconstruction images of the mandibular posterior areas in the CT-Scan.

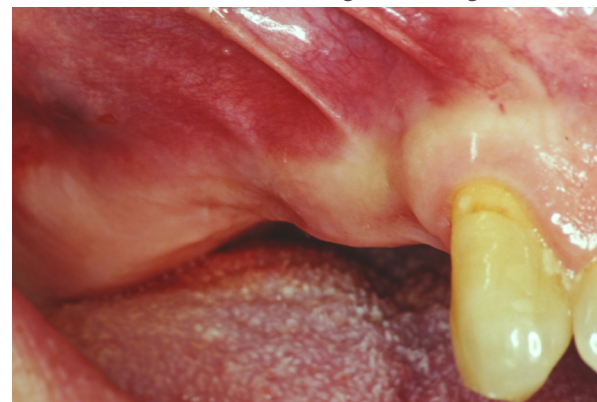
Case D (Figures 19-29)

The patient presented for treatment of the maxillary right quadrant, where all posterior teeth were missing. The initial clinical and radiographic examination with a panoramic x-ray showed medium absorption of the alveolar crest in height and width (Figure 19 and Figure 20). A full wax-up was performed on the area of the missing teeth, to determine the exact position and size of the teeth on the planned restoration that would indicate the most favorable position and inclination of the implants.

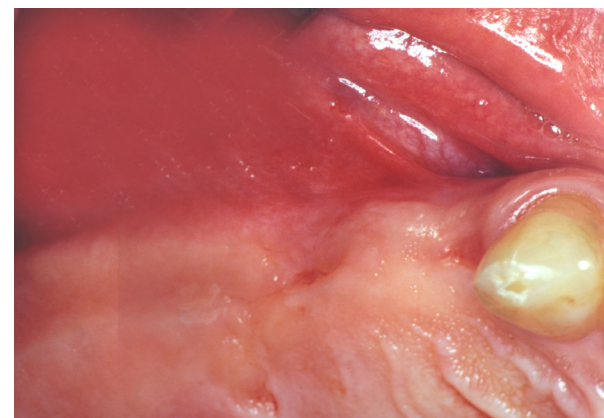On the study casts red lines were drawn to facilitate the wax-up for the dental technician (Figure 21). These lines were drawn arbitrarily without the proper attention. The wax-up was accomplished and a radiographic template was fabricated with radiopaque markers (Guttapercha) along the axes of the teeth. On the CT-Dental Scan that was taken with the radiographic template it was obvious the bone quantity allowed implant placement but the planned direction and drilling for the first premolar would result to severe injury of the canine (Figure 22a and Figures 22b). The study casts were re-examined taking under consideration the inclination of the canine root (Figures 23-24).

The surgical template was transformed accordingly; the surgical flap allowed visual examination of the canine root and the drilling for the first premolar was performed with low speed to the adequate inclination (Figures 25-

26). As a result the implants could be inserted without any injury on the root and the implants could be restored uneventfully (Figures 27-28). The implants and the restoration remain in function for long time (Figure 29).



19 (a)



19 (b)

Figure 19a and 19b: Case D: Initial clinical situation.

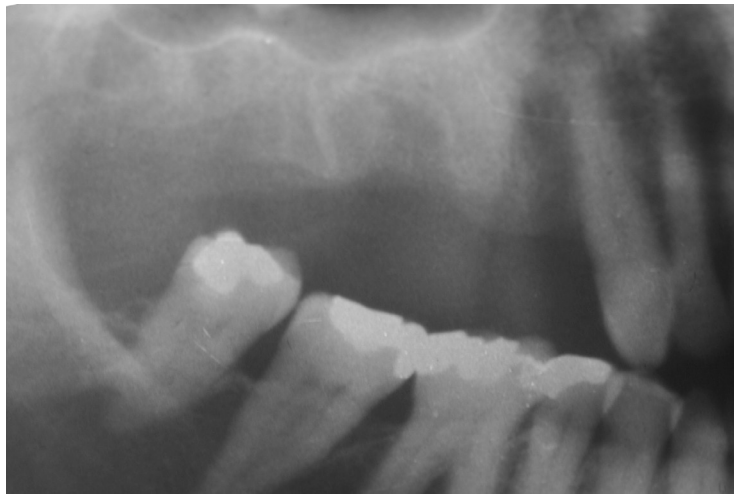

Figure 20: Panoramic x-ray.

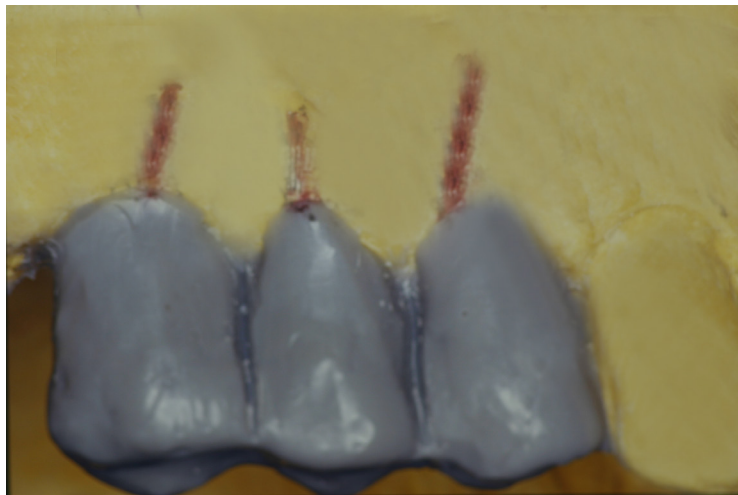
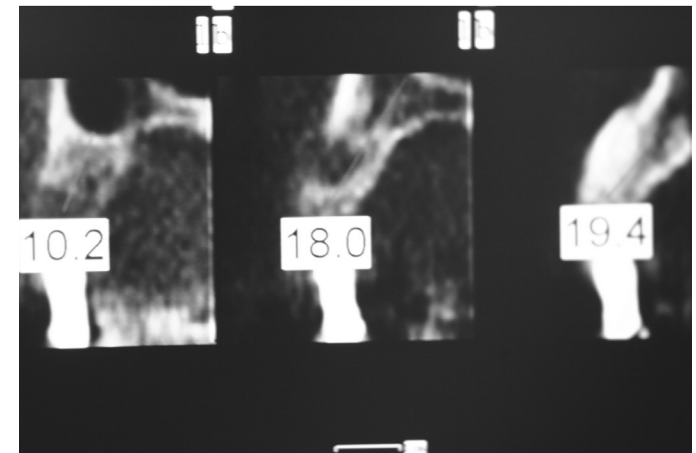


Figure 21: Study cast with the initial incorrect markings for the wax up.



22 (a)



22 (b)

Figure 22 a and 22b: CT-Scan of the area 13-17. There is adequate bone volume in width and height, but the planned insertion axis for the implant of the first premolar would result in injury of the canine.

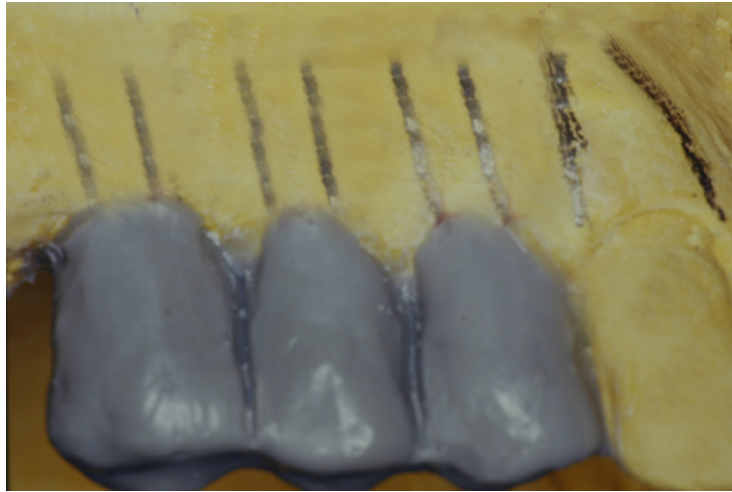


Figure 23: The study cast with markings for the root of the canine.

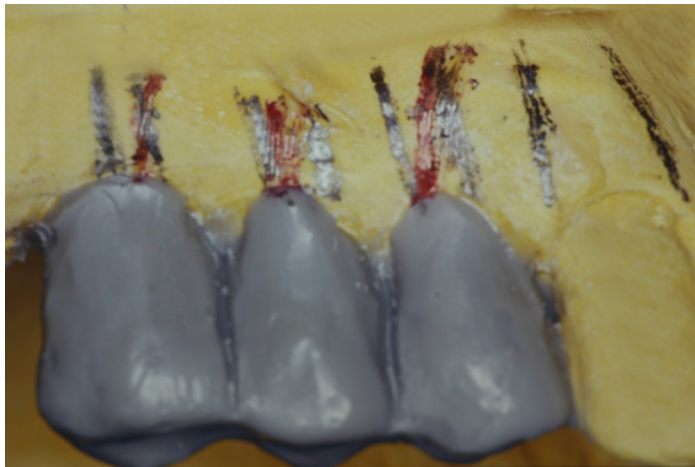


Figure 24: The study cast with the previous incorrect markings (red) and the corrected markings (black).

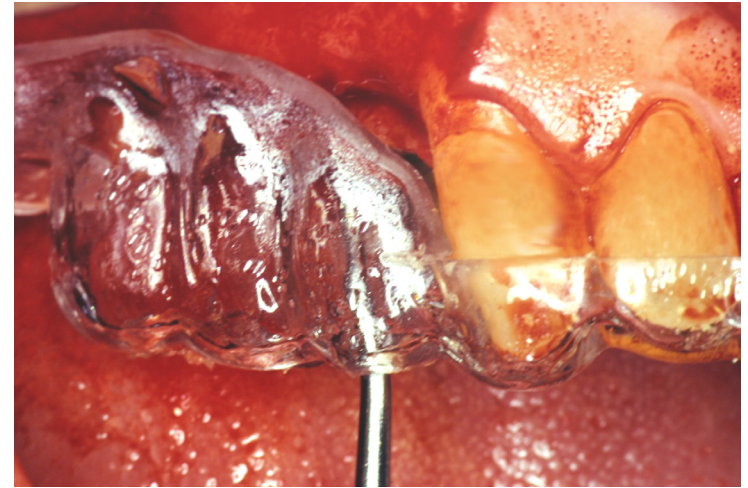


Figure 25: Initial drilling through the surgical template.

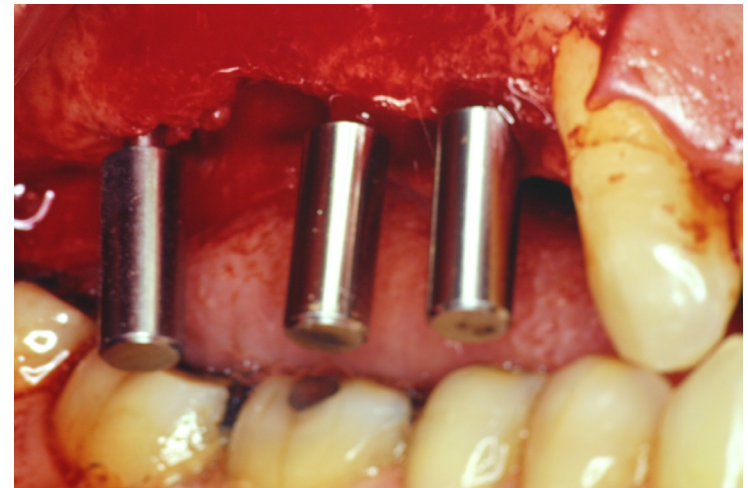

Figure 26: Positioning indexes after the first drilling.

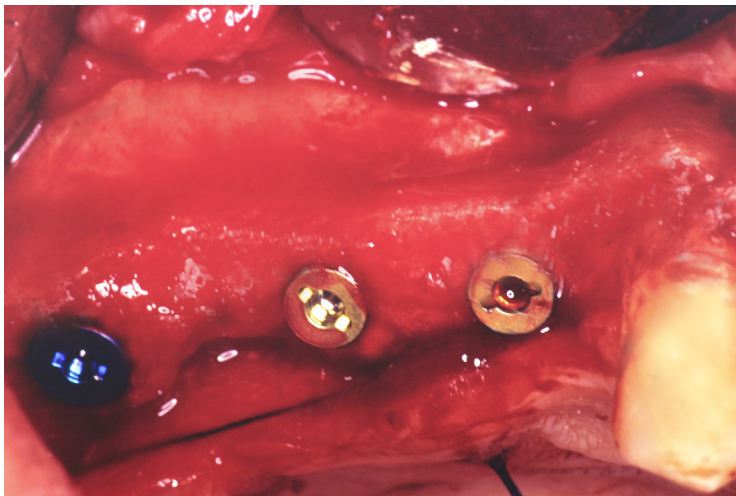


Figure 27: Implant placement.

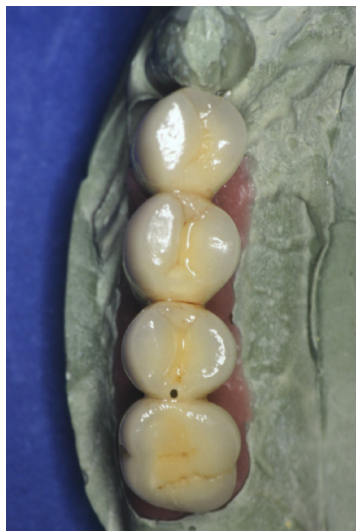

Figure 28: The final restoration.

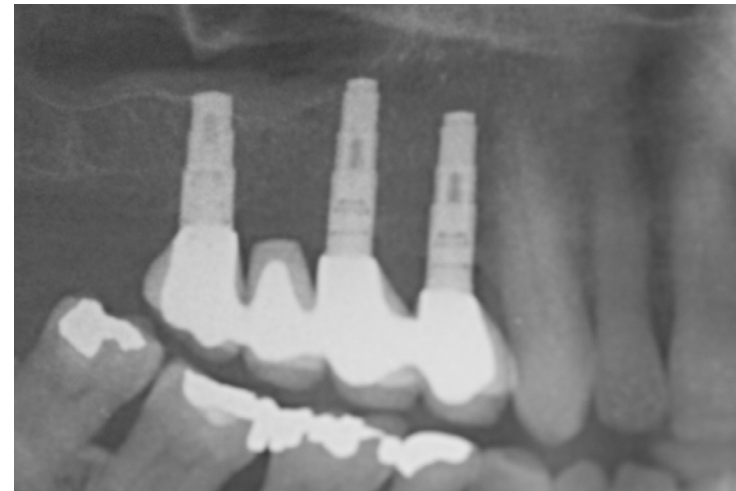


Figure 29: X-ray at the 12-years recall.

Case E (Figures 30-48)

Initial Treatment Steps

A 50 year old male Caucasian patient was referred for prosthetic restoration (Figure 30). The treatment plan included full-mouth rehabilitation with implant restorations. On the left side of the mandible the second premolar (# 35) had a poor prognosis and should be extracted. Single crowns for teeth #34 and # 37 were planned and two implant-supported crowns for the region of teeth # 35 and # 36. On the right side, two single implant crowns for areas of the second premolar and first molar (teeth # 45 and 46) were planned (Figure 31a and Figure 31b).

A radiographic template was fabricated from a thermoplastic Omnivac sheet as a duplicate from the diagnostic wax-up. The outer surfaces of the teeth on the radiographic template were covered with radiopaque material (amalgam powder diluted in transparent nail varnish) to indicate the contour of the planned restoration on the CT-Dental Scan. Guttapercha points were inserted in the center of the acrylic teeth along the planned implant axis (Figure 32).

The use of a radiographic template during Cone Beam Computer Tomography (CBCT) facilitates the orientation of the scanning level and the recognition of the exact areas of concern at the cross-section images [9-12]. This kind of radiographic template offers two significant advantages: The long axis of the implant is indicated from gutta-percha and the contour of the planned restoration is depicted from amalgam powder. It is also an easy and low cost technique requiring no additional equipment. Compared to other radiopaque materials such as barium sulfate or zinc foil, amalgam powder offers a sharper image with minimum thickness. Additionally, the fabricated radiographic template can be transformed to a surgical template in a very short time by removing the amalgam powder and the guttapercha points with diluting agents as acetone and chloroform.

Surgical Planning Based on CBCT and Comparison of Reconstructions

The patient was referred for a Cone Beam Computer Tomography (CBCT) with the radiographic template in situ. The desired shape of the planned restoration and its relation to the bone substrate could be clearly recognized. Furthermore inclination, length and diameter of the desired implants could be selected. For the mandibular left second premolar (# 35) a 4x15mm implant (Figure 33) and for the left first molar (# 36) a 4x13mm implant were initially selected (Figure 34).

On the CBCT it was observed that the transverse orientation lines - that are drawn before 3D reconstruction and serve as a frame for the cross-section images- were aligned parallel to the inferior border of the mandible and not parallel to the occlusal plane, as dictated from the radiographic template (Figure 35). For this reason, a new digital reconstruction of the existing CBCT was decided without exposing the patient to additional radiation. The base orientation line in the new reconstruction was parallel to the occlusal plane and new cross-section images were obtained. Consequently the inclination of the transverse images was altered compared to the previous reconstruction. The different orientation lines in the two reconstructions of the same CBCT can be clearly observed on (Figure 36a and Figures 36b).

Focusing on the definition of the occlusal plane for

the CBCT reconstruction there are two options can be applied: the occlusal plane can be recognized either by the teeth (if existing) or alternatively by the occlusal surfaces of the teeth on the radiographic template. In the described case, the occlusal plane as defined by the maxillary teeth was selected. Alternatively, the mandibular teeth on the radiographic template could have also been used as reference points (Figure 36a and Figures 36b).

In (Figure 37a and Figure 37b) the panoramic views of the two separate reconstructions are shown. The inclination of the guttapercha markers towards the long axis of the existing premolars was significantly influenced by the alignment of the scanning level. In the second reconstruction the guttapercha markers appeared parallel to the premolars, as they were originally placed during the laboratory fabrication of the radiographic template. The second reconstruction was obviously closer to the clinical situation with significantly less distortion.

When comparing the cross-section images from the two reconstructions, different morphology of the left side of the mandible was also observed. The inclination of the alveolar crest to the sagittal plane (labial-lingual) appeared different. Both the second premolar (Figure 38a and Figures 38b) and the first molar region (Figure 39a and Figure 39b) appeared significantly different in the cross-sections images. According to the second reconstruction, a 3.25x10mm implant (Figure 40) for the second premolar and a 4x10mm (Figure 41) for the first

molar region were selected. The implant length as initially planned was 15 mm for the premolar and 13 mm for the molar (compare to Figure 38 and Figure 39). The implant length that was finally selected was reduced to avoid any injury to the mandibular nerve.

The horizontal distance between the mental foramen and the crown of the second premolar (# 35)-as indicated by the radiopaque material on the radiographic template-also appeared different in the cross-section images in the two reconstructions (Figure 42a,b and Figures 43). In the first reconstruction, the second premolar crown (# 35)-as depicted on the radiographic template- appeared in cross-section image # 48 (Figure 42a). The mental foramen was observed in cross-section image # 52 (4 transverse images away), thus indicating a horizontal distance of 8mm (Figure 42b). In the second reconstruction (Figure 43), the mental foramen appeared right under the second premolar crown, on the same cross-section image #45. If the implant insertion was based on the images of the first reconstruction, an injury of the mental nerve would be possible due to the selected length and inclination of the implant.

In the presented case, the first CBCT reconstruction was performed using the inferior border of the mandible as an orientation line and resulted in distorted cross-sectional images. A second reconstruction of the existing CBCT, using the occlusal plane of the patient as an orientation line, produced cross-sectional images that depicted the alveolar crest more accurately. A possible explana-

tion for this finding may be the angle at which the cross-sectional images are produced. If the posterior areas of the mandible are considered as a cylinder that is “sliced” perpendicular to its long axis, the cross-sectional images appear as a circle with a certain diameter [19]. These images are closer to the clinical situation and to the surgical anatomy. If the cylinder is “sliced” to an angle declining from the perpendicular line, the cross-section is depicted as an ellipse with greater phenomenal diameter and increased height (Figure 44). The influence of the orientation line to the accuracy of the reconstruction and of the cross-section images has already been analyzed in details in a previous publication [19].

Modification of the Surgical Plan and Restoration

Based on the analysis of the images in the second reconstruction of the CBCT, the surgical plan was slightly modified aside from the implant length: The implant of the second premolar (# 35) was placed in the predetermined position but the axis was changed with a labial inclination according to the alveolar crest, to ensure a safe distance from the mental foramen. The implant for the first molar (#36) was shifted distally -closer to the second molar (#37) - to avoid creating an intra-coronal cantilever on the restoration (Figure 45a and Figures 45b).

After uneventful osseointegration, the prosthetic restoration was completed with inclined abutments to com-

pensate the divergence of implants (Figure 46). As it was already planned before implant placement, on the extended edentulous area of the mandibular left side (#34-37) a premolar was added between implant crowns # 35 and # 36 as a pontic (Figure 47). In this way, over contouring of the restoration and an intra-coronal cantilever on the implant-supported molar crown could be avoided. The implants showed no signs of complications or infection at the annual recall (Figure 48).

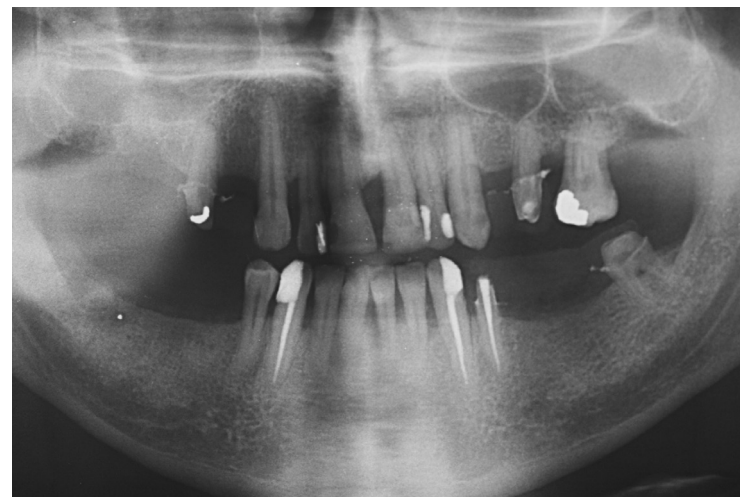
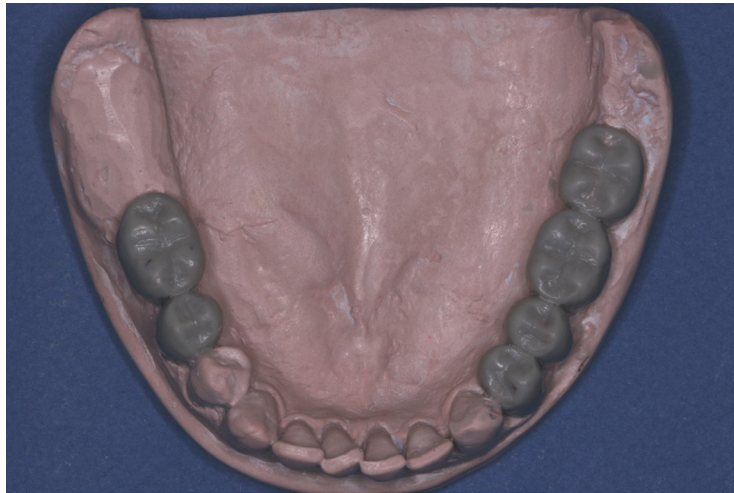
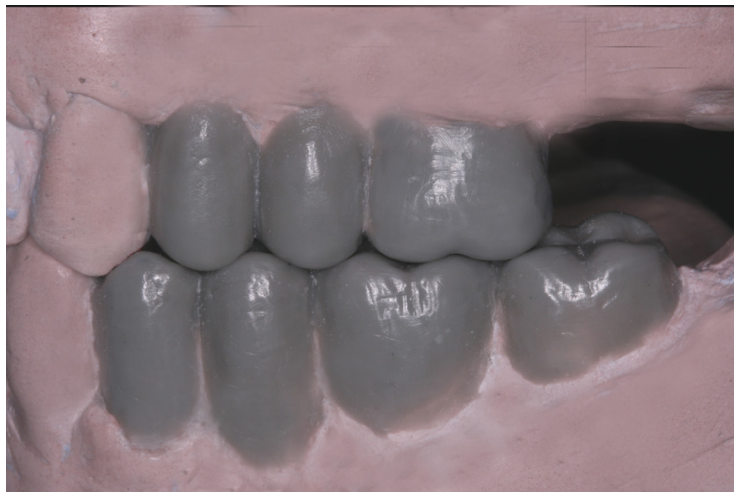
Figure 30: Case E: Initial radiographic examination.



31 (a)



31 (b)

Figure 31a and 31b: Diagnostic wax-up.

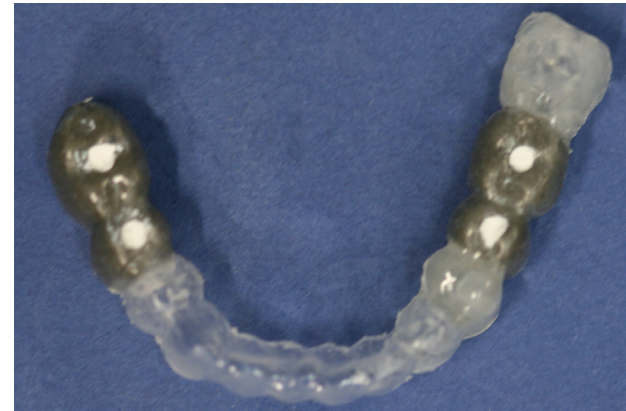

Figure 32: Radiographic template with radiopaque material (amalgam powder) to indicate the outline of the planned restoration and guttapercha for the implant axis on the CBCT.

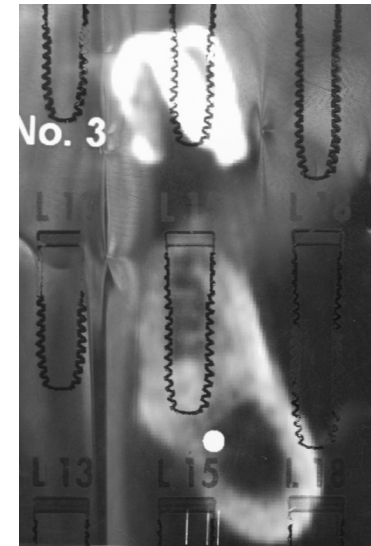


Figure 33: Cross-section image of the left mandibular second premolar region (# 35) at the first reconstruction. A 4x15 mm implant was initially selected.

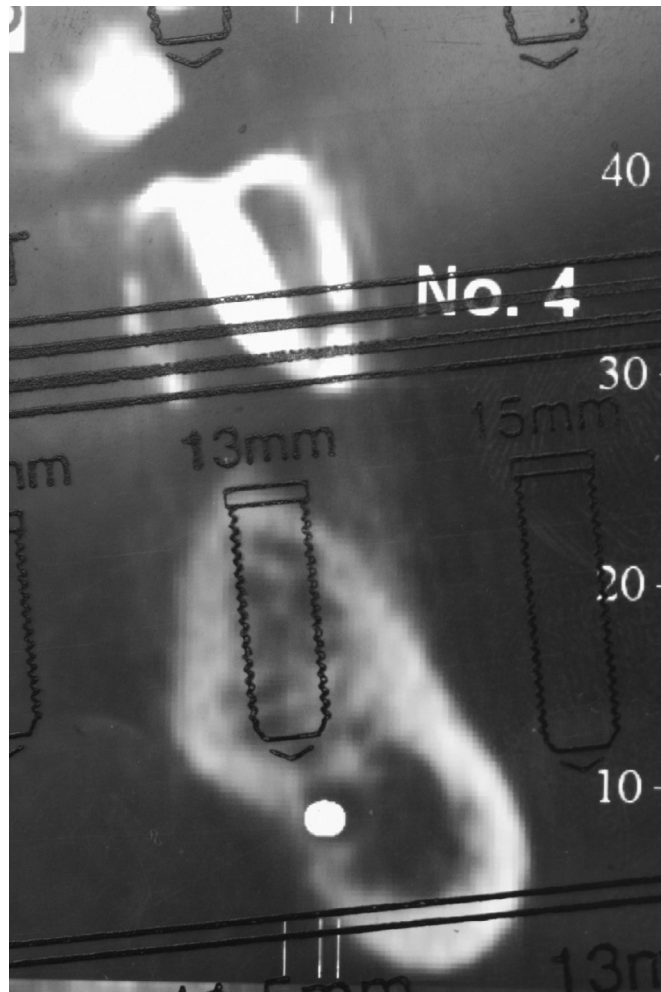


Figure 34: Cross-section image of the left mandibular first molar region (# 36) at the first reconstruction. A 4x13mm implant was initially selected..

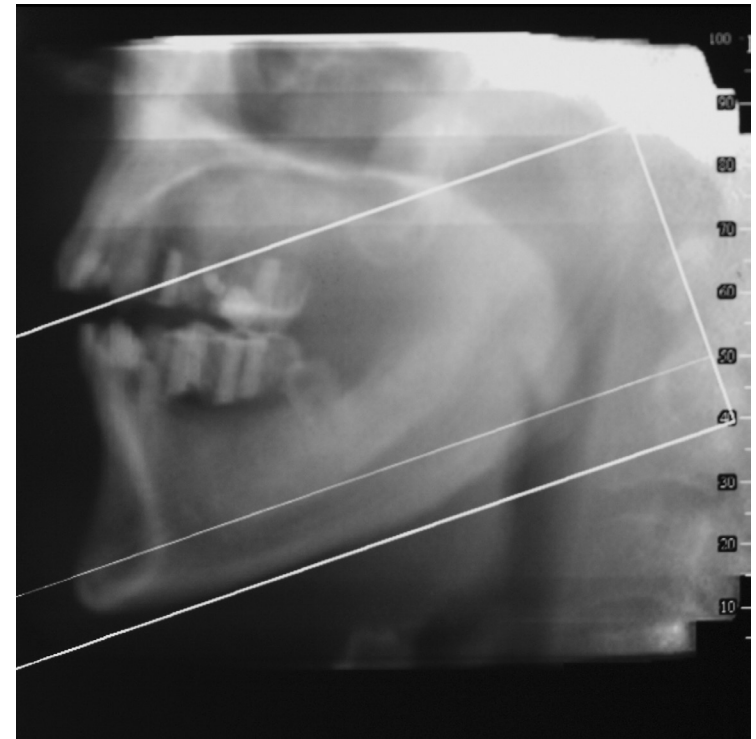
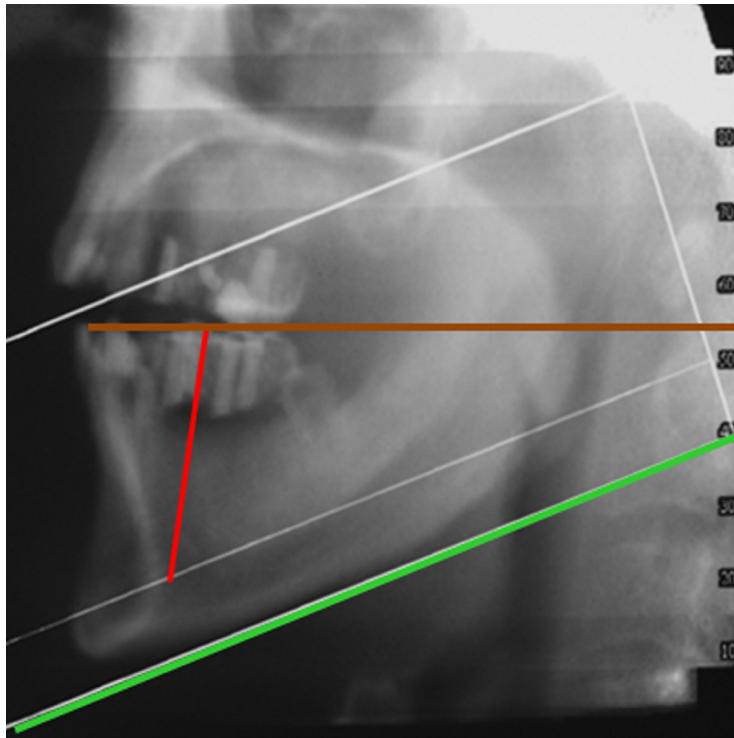
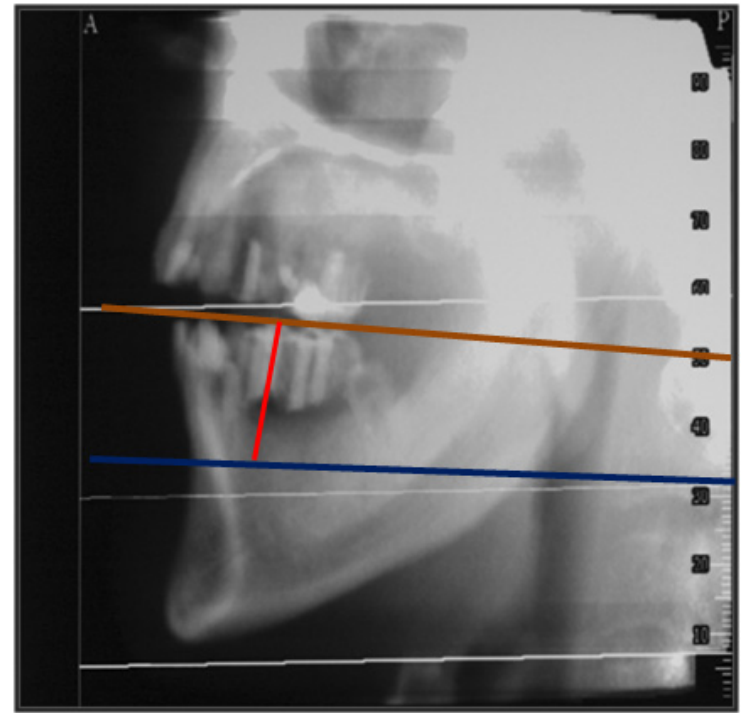


Figure 35: The transverse orientation lines were drawn parallel to the inferior border of the mandible and not parallel to the occlusal plane.

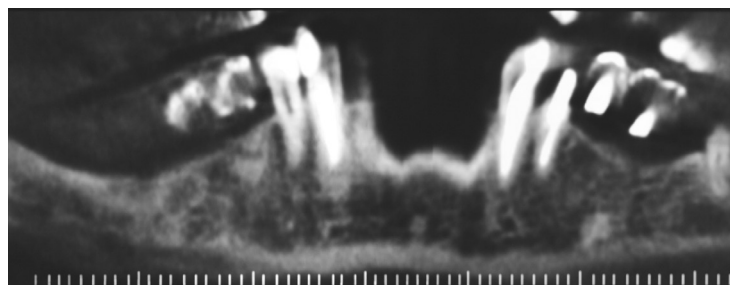


36 (a)

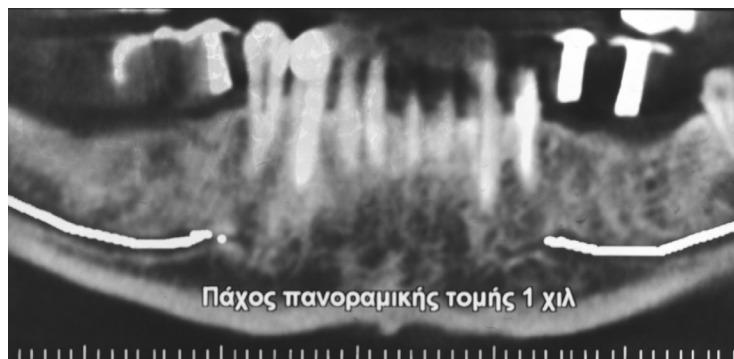


36 (b)

Figure 36a and 36b: The transverse orientation lines on the two reconstructions: a) The first reconstruction on the left and b) the second reconstruction on the right. Red: indicates the axis of the implant and the restoration, Yellow: indicates the occlusal plane as dictated by the radiographic template, Green: indicates the inferior border of the mandible, Blue: indicates an orientation line parallel to the occlusal plane.

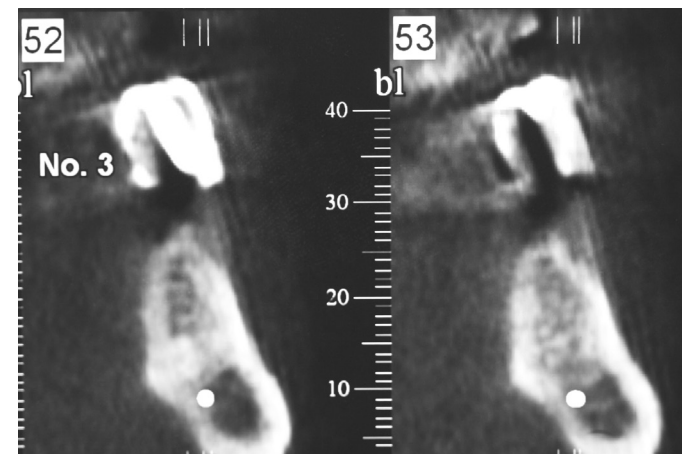


37 (a)

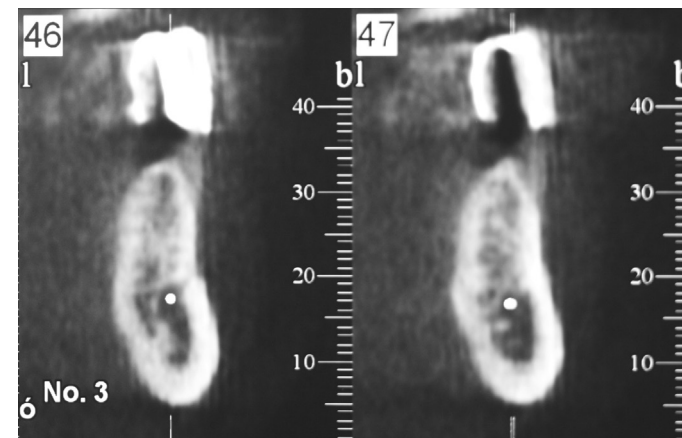


37 (b)

Figure 37a and 37b: Panoramic views of the two reconstructions: a) the first on the left side b) the second on the right. The second image shows less distortion.

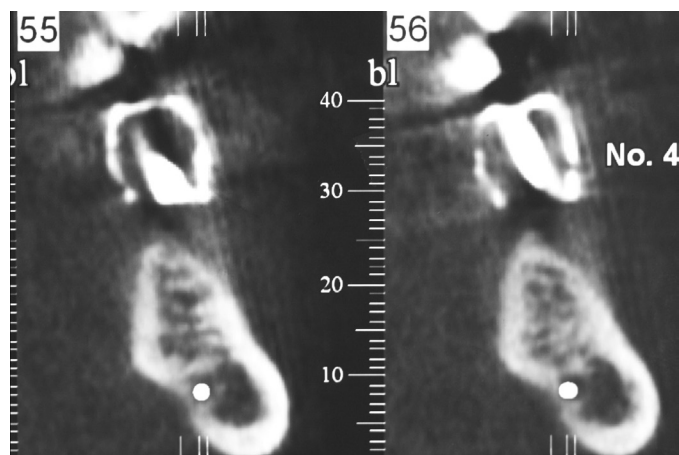


38 (a)

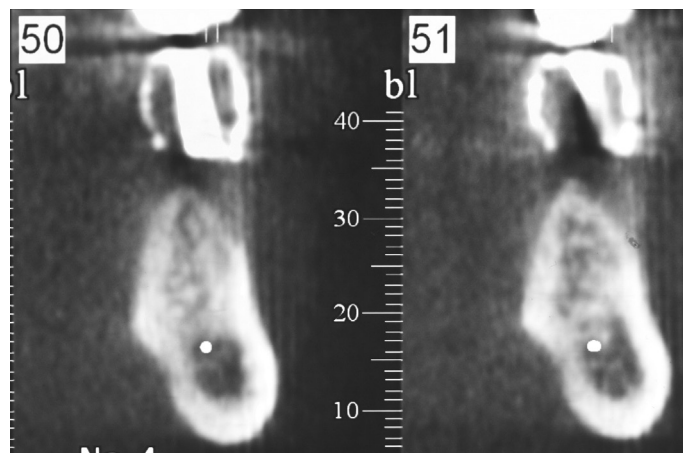


38 (b)

Figure 38a and 38b: Cross-sectional images of the mandibular second premolar region (# 35): a) On the left is the first reconstruction and b) on the right the second one. The difference in the morphology of the alveolar ridge is obvious.



39 (a)



39 (b)

Figure 39a and 39b: Cross-section images of the mandibular first molar region (# 36): a) On the left is the first reconstruction and b) on the right the second one. The difference in the depicted morphology of the alveolar ridge is obvious.

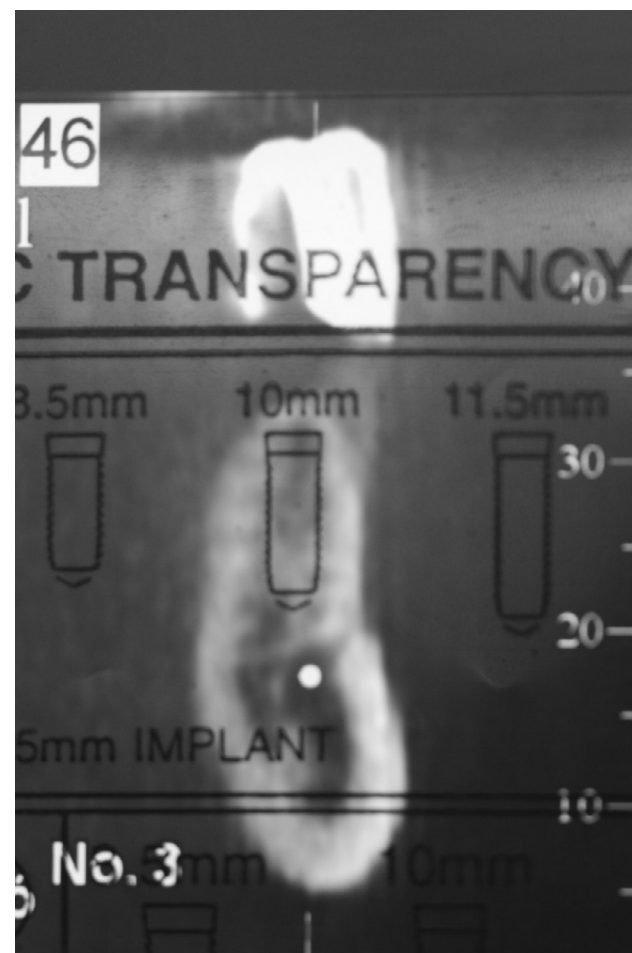


Figure 40: A 3.25x10 mm implant was finally selected for the second premolar region (# 35) according to the second reconstruction. Compare with Figure 33.

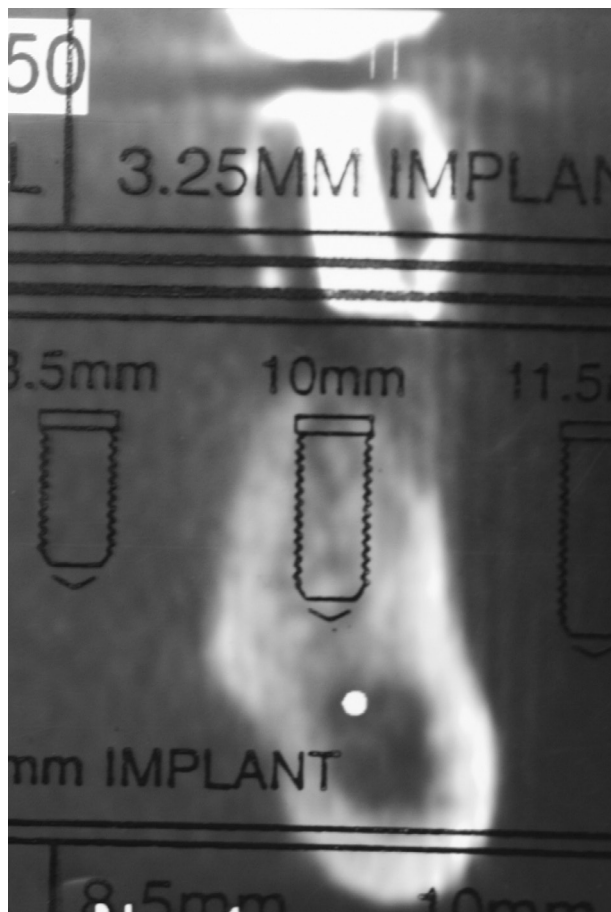
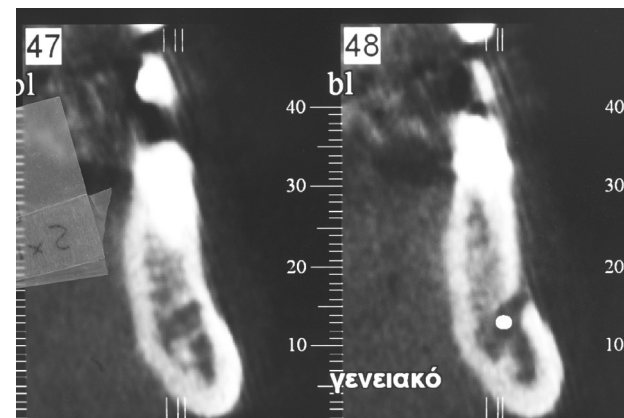
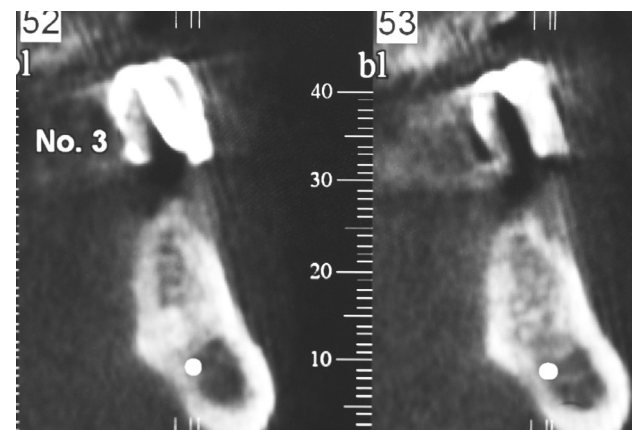


Figure 41: A 4x10mm implant was finally selected for the first molar region (# 36) according to the second reconstruction. Compare with Figure 34.



42 (a)



42 (b)

Figure 42: The left mandibular premolar area on the first reconstruction. a) the mental foramen appeared at cross-section image # 48. b) the crown of the 2nd premolar (region # 35) - as depicted by the radiographic template- was observed after 4 crosssections (#52) indicating 8 mm distance.

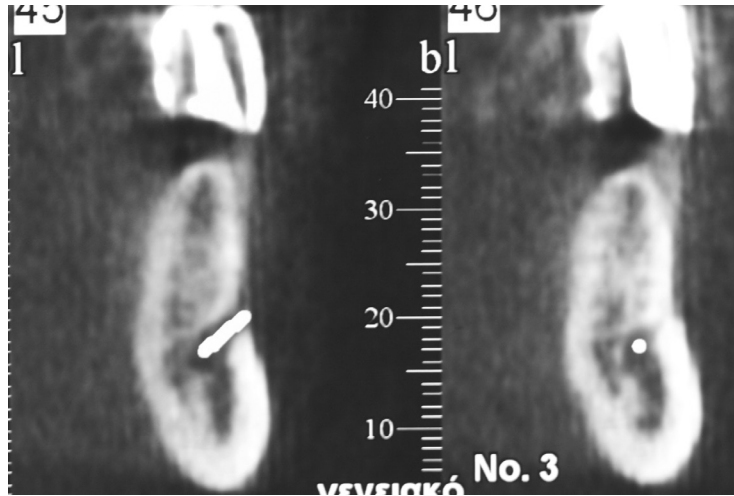


Figure 43: At the second reconstruction the mental foramen appeared underneath the crown of second premolar (# 35), as depicted from the radiographic template.

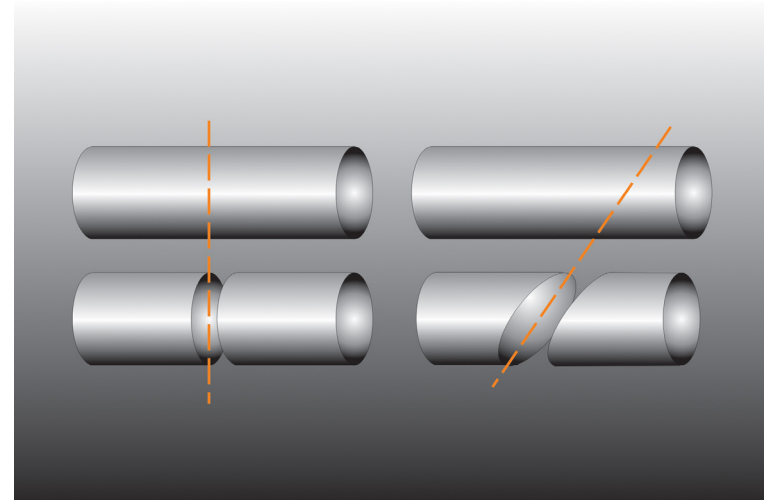
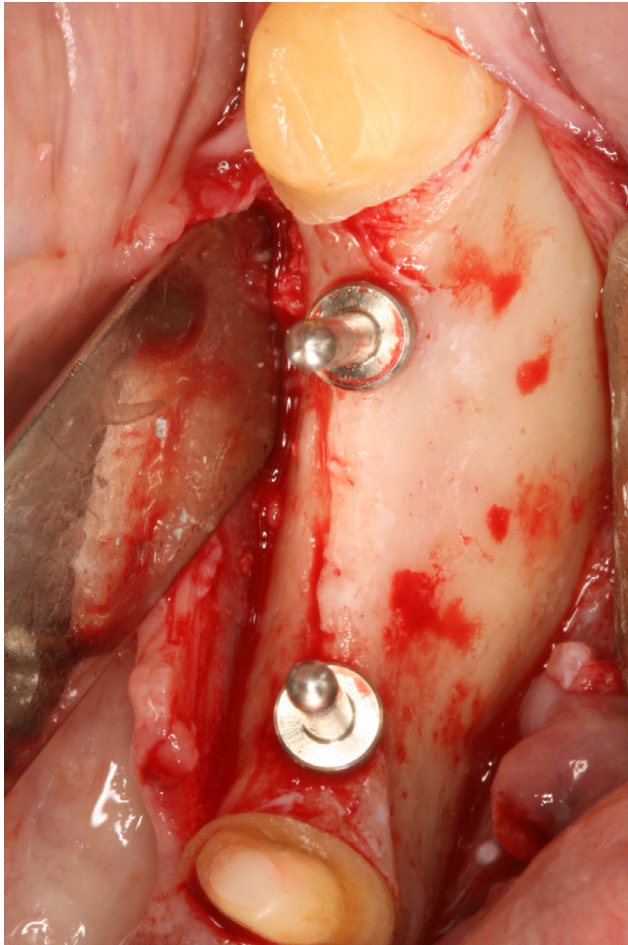
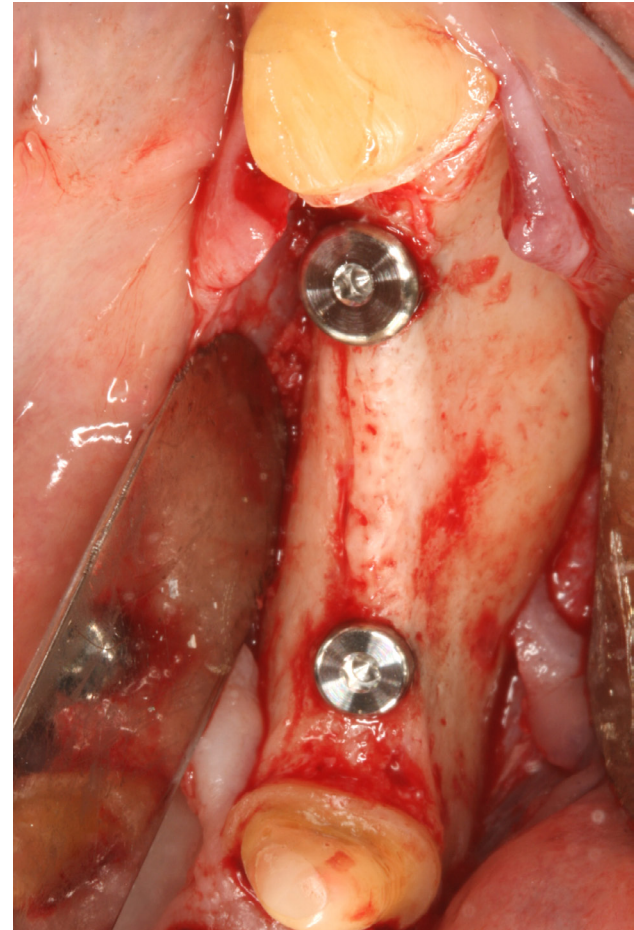


Figure 44: Diagrammatic cross-sections of a cylinder sliced perpendicular to its long axis (left) and with side inclination (right). From Kourtis et al (2012)[19].



45 (a)



45 (b)

Figure 45a and 45b: The positioning indexes and the implants after insertion. (Courtesy of Dr. E Skondra).

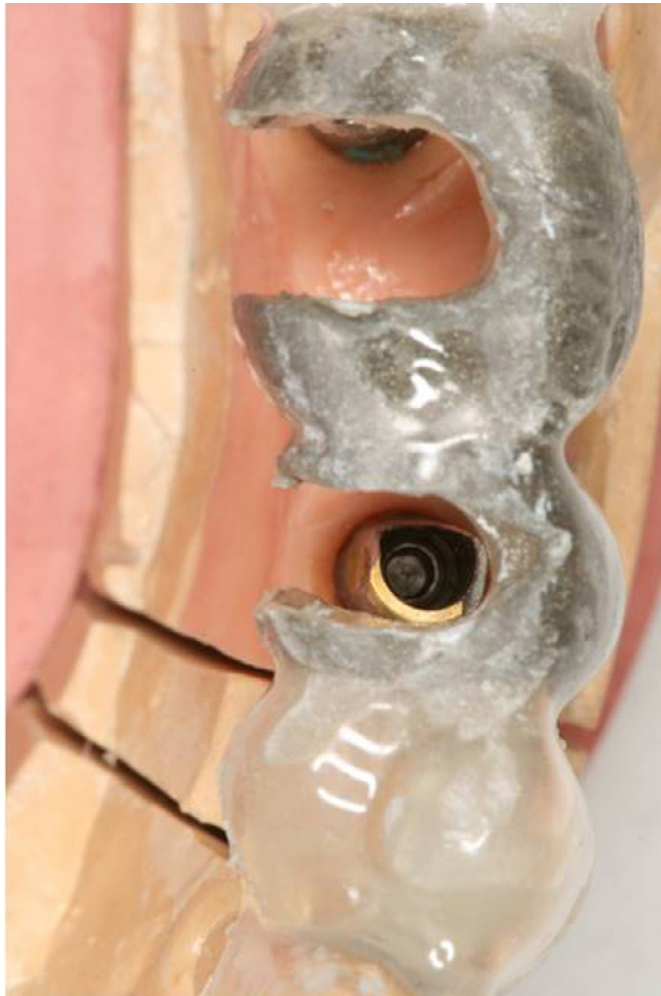

Figure 46: The surgical template on the working cast. The implant for the first molar (# 36) has been shifted distally according to the modified surgical plan to avoid overcontouring. (Courtesy of Dr. E Skondra).

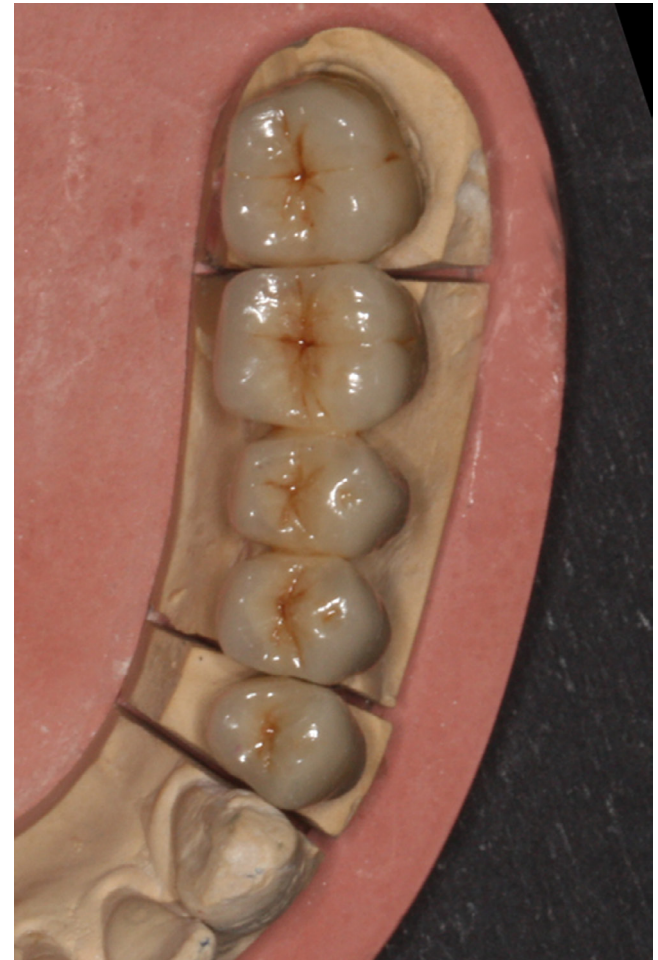

Figure 47: The restorations on the working cast. A premolar has been added between the implant crowns to avoid overcontouring of the restoration. (Courtesy of Dr. E Skondra).

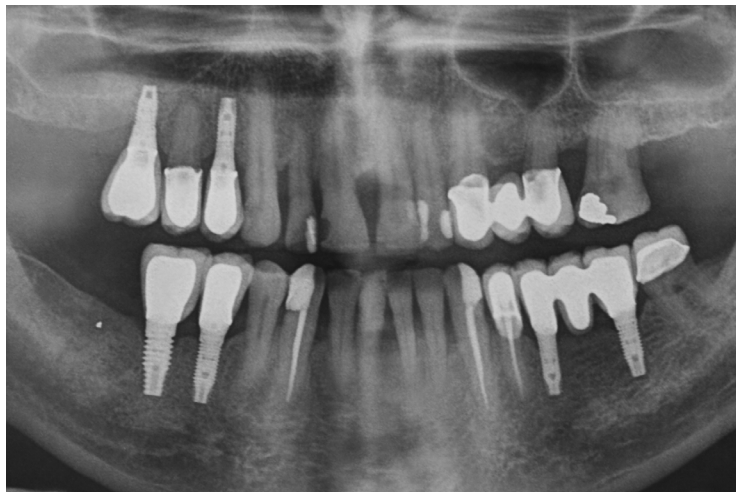

Figure 48: Radiographic examination at the annual recall. The mental foramen is located right underneath the implant# 35, as was noted at the second image reconstruction of the CT-Scan.

Discussion

Presurgical planning is a crucial stage in implant restorations, both in the surgical and the prosthetic phase. Its need has been emphasized from the early years of osseointegration but the extended possibilities offered by the augmentation techniques have also underlined the importance of the detailed treatment planning. Although digital solutions (CAD/CAM planning, guided implant insertion) gain more ground in the everyday practice, the clinician should always be able to make a precise treatment

planning based on the established clinical and laboratory procedures. Even the most evolved digital systems have a degree of inaccuracy and the end result remains always the responsibility of the clinician [16-18]. For these reasons it remains essential-even if a digital system is being used- that the clinician can and should check and confirm the proposed treatment plan based on his extended knowledge of the whole procedure [19,20].

References

1. Arlin ML. Optimal placement of osseointegrated implants. *J Can Dent Assoc.* 1990; 56: 873-876.
2. Wolf M. [Teamwork and communication in implantology: dentist--technician--implant surgeon]. *Int J Dent Symp.* 1994; 2: 12-15.
3. Buck MB. Presurgical prosthetic case planning for oral reconstruction utilizing implants. *J Oral Implantol.* 1996; 22: 68-69.
4. Callan DP, Strong S. Creating the environment for implant success: an interdisciplinary approach. *Int J Dent Symp.* 1995; 3: 48-51.
5. Lang M. Professional cooperation between dentist and laboratory technician. *Implant Dent.* 1999; 8: 25-28.
6. Jansen CE, Weisgold A. Presurgical treatment planning for the anterior single-tooth implant restoration. *Compend Contin Educ Dent.* 1995; 16:

746, 748-752, 754 passim.

7. Kourtis S, Kokkinos K, Roussou V. Predicting the final result in implant-supported fixed restorations for completely edentulous patients. *J Esthet Restor Dent*. 2014; 26: 40-47.
8. Takeshita F, Tokoshima T, Suetsugu T. A stent for presurgical evaluation of implant placement. *J Prosthet Dent*. 1997; 77: 36-38.
9. Israelson H, Plemons JM, Watkins P, Sory C. Barium-coated surgical stents and computer-assisted tomography in the preoperative assessment of dental implant patients. *Int J Periodontics Restorative Dent*. 1992; 12: 52-61.
10. Solow RA. Simplified radiographic-surgical template for placement of multiple, parallel implants. *J Prosthet Dent*. 2001; 85: 26-29.
11. Ku YC, Shen YF. Fabrication of a radiographic and surgical stent for implants with a vacuum former. *J Prosthet Dent*. 2000; 83: 252-253.
12. Forbes-Haley CE, King PA. Markers for implant placement in CBCT: a technical overview. *Eur J Prosthodont Restor Dent*. 2013; 21: 157-160.
13. De Kok IJ, Thalji G, Bryington M, Cooper LF. Radiographic stents: integrating treatment planning and implant placement. *Dent Clin North Am*. 2014; 58: 181-192.
14. Ganz SD. Cone beam computed tomography-assisted treatment planning concepts. *Dent Clin North Am*. 2011; 55: 515-536.
15. Angelopoulos C, Aghaloo T. Imaging technology in implant diagnosis. *Dent Clin North Am*. 2011; 55: 141-158.
16. Turbush SK, Turkeyilmaz I. Accuracy of three different types of stereolithographic surgical guide in implant placement: an in vitro study. *J Prosthet Dent*. 2012; 108: 181-188.
17. Platzer S, Bertha G, Heschl A, Wegscheider WA, Lorenzoni M. Three-dimensional accuracy of guided implant placement: indirect assessment of clinical outcomes. *Clin Implant Dent Relat Res*. 2013; 15: 724-734.
18. Hu KS, Choi DY, Lee WJ, Kim HJ, Jung UW. Reliability of two different presurgical preparation methods for implant dentistry based on panoramic radiography and cone-beam computed tomography in cadavers. *J Periodontal Implant Sci*. 2012; 42: 39-44.
19. Kourtis S, Skondra E, Roussou I, Skondras EV. Presurgical planning in implant restorations: correct interpretation of cone-beam computed tomography for improved imaging. *J Esthet Restor Dent*. 2012; 24: 321-332.
20. Binon PP. Treatment planning complications and surgical miscues. *J Oral Maxillofac Surg*. 2007; 65: 73-92.